

Human Hippocampal Activation in the Delayed Matching- and Nonmatching-to-Sample Memory Tasks: An Event-Related Functional MRI Approach

Christopher S. Monk, Jiancheng Zhuang,
and W. John Curtis
University of Minnesota, Twin Cities

Iris-Tatjana Ofenloch
University of Konstanz

Nim Tottenham, Charles A. Nelson, and Xiaoping Hu
University of Minnesota, Twin Cities

The delayed matching-to-sample (DMS) and delayed nonmatching-to-sample (DNMS) memory tasks are standard tools used to probe visual recognition memory in human and nonhuman primates. Previous research indicates that structures within the medial temporal lobe, including the hippocampus, make up a crucial memory circuit for successful performance on these tasks. In the present investigation, event-related functional magnetic resonance imaging was used to examine activation in the hippocampus proper during these memory tasks relative to a perceptuomotor task involving the same stimuli. The results indicate that both memory tasks elicited greater activation in the right hippocampus during the encoding phase. These findings are consistent with the work from human patients and animal studies, indicating hippocampal involvement in the DMS and DNMS tasks.

The structures that make up the medial temporal lobe (MTL) have been implicated in memory for at least 100 years (von Bechterew, 1900), but it is still unclear which structures (hippocampus, parahippocampus, amygdala, and rhinal cortex) are necessary and which aspects of memory recruit these structures (e.g., Murray & Mishkin, 1998; Zola et al., 2000). Scoville and Milner (1957) examined patients who underwent resection of the MTL that sometimes included the hippocampus. Memory deficits were found only when the hippocampal region was damaged. More recently, autopsy of patient R. B., who had developed memory impairments following an ischemic episode, revealed that

the damage was limited to the CA1 hippocampal region (Zola-Morgan, Squire, & Amaral, 1986).

Research with human patients has been complemented by the development of an animal model for amnesia (Correll & Scoville, 1965; Mahut & Cordeau, 1963; Orbach, Milner, & Rasmussen, 1960). Often the delayed-matching-to-sample (DMS) task or the delayed nonmatching-to-sample (DNMS) task is used with monkeys to measure memory (Gaffan, 1974; Mishkin & Delacour, 1975). In these tasks, monkeys are trained to choose a sample stimulus. The sample is then presented with another stimulus, and the monkey learns to choose the old (DMS) or new stimulus (DNMS). Once the task is learned, delays are placed between the initial presentation and the test. Damage to the monkey hippocampus typically leads to memory impairments, as measured by DNMS (Alvarez, Zola-Morgan, & Squire, 1995; Mahut, Zola-Morgan, & Moss, 1982; Zola et al., 2000; Zola-Morgan, Squire, Rempel, Clower, & Amaral, 1992; but see Murray & Mishkin, 1998), with delays of at least 15 s revealing memory deficits (Zola et al., 2000). Furthermore, humans with damage to the hippocampus and amygdala are impaired on DMS (Owen, Sahakian, Semple, Polkey, & Robbins, 1995).

Further complementing the neuropsychological research on the human and nonhuman primates are functional neuroanatomical studies with healthy subjects. It has been found that metabolic rate increases in the hippocampus as monkeys perform the delayed object alternation, a task that is similar to DNMS (Friedman & Goldman-Rakic, 1988). Moreover, functional magnetic resonance imaging (fMRI) and indwelling electrode studies with humans

Christopher S. Monk and W. John Curtis, Institute of Child Development and Center for Cognitive Sciences, University of Minnesota, Twin Cities; Jiancheng Zhuang and Xiaoping Hu, Center for Magnetic Resonance Research and Center for Cognitive Sciences, University of Minnesota, Twin Cities; Iris-Tatjana Ofenloch, Department of Psychology, University of Konstanz, Konstanz, Germany; Nim Tottenham, Institute of Child Development, University of Minnesota, Twin Cities; Charles A. Nelson, Institute of Child Development, Center for Cognitive Sciences, and Department of Pediatrics, University of Minnesota, Twin Cities.

This research was made possible by National Institutes of Health (NIH) Grants NS34458 and NS32976 to Charles A. Nelson, NIH Grant MH55346 to Xiaoping Hu, NIH Grant 5T32HD0715 to the Center for Cognitive Sciences, and National Center for Research Resources Grant P41RR08079.

Correspondence concerning this article should be addressed to Christopher S. Monk, who is now at the Section on Development and Affective Neuroscience, National Institute of Mental Health, Building 15K, Room 204, Bethesda, Maryland 20892-2670. E-mail: christopher.monk@nih.gov

indicate that hippocampal activity at encoding is related to later memory performance (Fernández et al., 1998, 1999).

Alone, however, findings from participants with brain damage and functional neuroanatomical studies are limited. Research with brain-damaged individuals does not describe the function of the damaged structure; it merely illustrates the functioning of the brain without that region (Gabrieli, 1998). In contrast, functional imaging only shows which neural regions are active; it does not establish whether that area is necessary. Few studies have adapted tasks from one approach to evaluate the findings with another technique. In the present investigation, fMRI was used to evaluate the role of the hippocampus in the DMS and DNMS tasks. fMRI measures blood oxygenation level-dependent (BOLD) activity, which is partly an indirect index of blood flow. The BOLD signal response is relatively delayed and prolonged compared with neural activity. Following a checkerboard stimulus presentation of 2 s, the positive BOLD phase begins in the cortex approximately 2–3 s following stimulus onset, reaches maximum between 6.0 and 7.4 s, and resolves between approximately 12 and 14 s (Janz, Schmitt, Speck, & Hennig, 2000).

While Elliott and Dolan (1999) examined the DMS and DNMS tasks with fMRI, they used a block design, whereby activity in one condition was compared with another over a block of time. In the present study, event-related fMRI was used and image acquisition targeted the hippocampus. Thus, rather than imaging the entire brain, this technique permits monitoring of a neural structure at a higher rate. Therefore, this investigation could more precisely determine whether these tasks activated the hippocampus proper (CA regions, dentate, and subiculum) relative to a perceptuomotor task. Furthermore, with the understanding of the delayed time course of the BOLD signal, it is possible to determine whether encode, test, or both phases recruit the hippocampus.

Method

Participants

Eight right-handed volunteers (4 women and 4 men) participated. Participants were 20–29 years of age with normal or corrected-to-normal vision and no history of neurological disorders. All participants provided informed consent, and the procedures were approved by the University of Minnesota Internal Review Board.

Task Design

Participants were administered DMS, DNMS, and perceptuomotor control tasks. The stimuli utilized were adapted from the DMS subscale of the Cambridge Neuropsychological Testing Automated Battery (Sahakian & Owen, 1992; Fray, Robbins, & Sahakian, 1996). They consisted of four adjoining colored squares, which made up one large square and subtended a visual angle of $3^\circ \times 3^\circ$. Within each of the four squares, there were varying numbers of abstract patterns.

The stimuli were generated from a Macintosh computer using PsyScope (Cohen, MacWhinney, Flatt, & Provost, 1993), and a projector (LP 420, Infocus, Wilsonville, OR) presented the images onto a screen outside of the scanner. Participants viewed the stimuli on a mirror attached to the head coil directly above their eyes. A triggering mechanism delivered a signal from the scanner to the computer to initiate the stimuli display.

During data acquisition, participants were administered the tasks in a total of six blocks consisting of nine experimental trials each. Two blocks of the DMS, DNMS, and perceptuomotor control tasks were presented,

with each of the three conditions administered in two consecutive blocks of trials. The order of conditions and stimuli was randomized across subjects. For all conditions, a trial consisted of a 3-s encoding period (Phase 1) followed by a 15-s delay (Phase 2), a 3-s test period (Phase 3), and, finally, a 12-s intertrial interval (Phase 4). The total trial length was 33 s.

For the DMS and DNMS tasks, participants saw a single stimulus during encoding (Phase 1) and then two stimuli side by side during testing (Phase 3). During Phase 1, participants were instructed to remember the stimulus and press one of two buttons (it did not matter which button was pressed; this motor response was only necessary to keep this task consistent with the perceptuomotor task, which is described later). In Phase 3, participants were asked to choose the familiar (DMS) or the unfamiliar (DNMS) stimulus. To indicate their selection, participants used their right index finger to press one of two buttons on a nonmetallic button box. The left button corresponded to the stimulus on the left side of the screen, and the right button corresponded to the stimulus to the right. For the perceptuomotor control condition, the same stimulus presentation was used. Participants saw one stimulus presented in Phase 1, they were instructed to press the left button if there was an odd number of colors in the stimulus and the right button if there was an even number. In Phase 3, participants were presented with two stimuli, and they were instructed to count the number of colors in the two stimuli and indicate again whether there was an odd or an even number of colors.

Procedure

Upon arrival at the laboratory, participants were given a medical history questionnaire to fill out. The questionnaire screened for neurological problems and conditions that might be adversely affected by participating in an MRI study. Participants were trained to perform the tasks and were then placed in the MRI for approximately 45 min.

Image Acquisition

Images were acquired by using a whole-body 1.5-Tesla Siemens (Munich, Germany) Vision clinical MRI system with a standard head coil. To monitor the BOLD signal, a T2*-weighted echo planar imaging (EPI) sequence was used to acquire four sagittal slices within the hippocampus: two in each hemisphere. Sagittal acquisition permits a greater proportion of the hippocampus to be imaged per slice than does coronal acquisition. Furthermore, in pilot testing, it was determined that sagittal imaging yielded less noise than axial slices. For the EPI sequence, the following parameters were used: TR = 750 ms, TE = 50 ms, flip angle = 75° , slice thickness = 7 mm, imaging matrix = 64×64 , and field of view = 24×24 cm². For each 33-s trial, 44 functional images were collected.

T1-weighted anatomic images were collected following the acquisition of the EPI. These data were obtained in the same plane as the functional images (imaging matrix = 256×256).

Data Analysis

For the behavioral data, accuracy and reaction time for the button press responses were measured. Separate ANOVAs were conducted. For significant differences, Fisher's least significant difference (LSD) tests were used.

The BOLD signal was analyzed with STIMULATE software (Strupp, 1997) and was confined to all voxels in the hippocampus (region of interest). The boundaries for the sagittal slice of the hippocampus were determined in accordance with Duvernoy (1991). The lateral ventricle made up the posterior boundary, the anterior border was the amygdala, the parahippocampal gyrus represented the ventral boundary, and the internal capsule was the dorsal border. Tracings for the left and right hippocampi were made separately for each participant; within each participant the same tracing was used across tasks.

Pilot work documented pronounced hippocampal activation during the encoding and test phases for the memory tasks. Therefore, for this analysis, the goal was to examine each participant's hippocampal activation in each hemisphere for Phases 1 and 3 of each task. Determination of the placement and size of the window that would be used to capture the BOLD response involved four steps. First, different durations (i.e., lengths) for the time window were computed for each phase and hemisphere, but these durations were the same across tasks and participants. The duration of each window was determined by calculating the average duration of positive activation (i.e., when the BOLD signal exhibited a positive percentage change) across participants and tasks. Percentage change was calculated with the equation $[(X - M) \div M] \times 100$ for each participant, where X is the BOLD signal value at a given point, and M is the mean BOLD signal across the 33-s task. Second, maximum point of activation for each participant within a task, phase, and hemisphere were determined. Following Janz et al. (2000), it was expected that the BOLD response would commence approximately 3 s following stimulus onset and resolve within 12 s. Therefore, the peak response that occurred within this time frame was included in the analysis. Third, the time windows were positioned on each participant's BOLD signal time course so that his or her peak level of activation was at the midpoint of the time window. Fourth, the mean amplitude, measured as a percentage change, was then derived from the time window of each participant, hemisphere, task, and phase (Phases 1 and 3).

Separate ANOVAs were used to examine differences in the percentage change of the BOLD signal among the three conditions within each phase and hemisphere. Significant differences were followed up with Fisher's LSD test.

Results

Behavioral Data

The means and standard deviations for accuracy, as well as reaction times, are presented in Table 1. Separate ANOVAs were conducted on Phases 1 and 3 on the behavioral results. During the first phase when participants pressed one of two buttons during encoding or color counting, no differences due to task were revealed for accuracy, $F(2, 14) = 2.03, p = .185$, and no differences were found for reaction time, $F(2, 14) = 1.02, p = .354$. In Phase 3 when participants pressed the button for the location of the previously seen stimulus (DMS), novel stimulus (DNMS), or the number of colors (perceptuomotor control), no significant differences were found for accuracy, $F(2, 14) = 0.15, p = .812$. Similarly, for button press reaction time at Phase 1, there were no effects of task, $F(2, 14) = 1.02, p = .354$. However, there were significant differences among these tasks for reaction time at Phase 3, $F(2, 14) = 15.49, p < .005$. Additionally, Fisher's LSD post hoc comparison showed that the reaction time was significantly faster for DMS compared with color counting ($p < .001$), and DNMS

was significantly faster than color counting ($p < .001$), but there were no differences between DMS and DNMS.

fMRI Data

Hippocampal activation patterns for each task and hemisphere are presented in Figure 1. The lag in the time course of the BOLD signal relative to the task demands is similar to other fMRI investigations (Buckner, 1998; Janz et al., 2000). In particular, following onset of Phases 1 and 3, the response occurs following approximately 3 s and continues for 11–12 s. ANOVAs were carried out on the activation pattern from the hippocampus in each hemisphere and Phases 1 and 3. For the encoding phase in the right hippocampus, significant differences were found among tasks, $F(2, 14) = 8.26, p < .005$. Moreover, an LSD post hoc comparison revealed that the DMS task yielded significantly larger activation than the color task ($p < .002$), and the DNMS task had significantly larger activation than the color task ($p < .04$), but there were no differences between the DMS and DNMS tasks.

An ANOVA comparing activation among the tasks at test revealed a trend, but no significant differences, $F(2, 14) = 3.45, p = .06$. No significant differences were found in the left hippocampus. For the encoding phase in the left hippocampus, there was also no effect from the tasks, $F(2, 14) = 2.06, p = .165$. Finally, for the test phase of the left hippocampus, there was no effect of task, $F(2, 14) = 0.28, p = .758$.

Discussion

The results from the present study indicate that both the DMS and DNMS memory tasks recruit the hippocampus in the right hemisphere during encoding. Previous findings from the neurophysiological literature (Owen et al., 1995) and research with nonhuman primates (Alvarez et al., 1995; Mahut, Zola-Morgan, & Moss, 1982; Zola et al., 2000; Zola-Morgan et al., 1992) demonstrate that memory performance in the DMS and DNMS tasks is impaired when the hippocampal formation, and perhaps the hippocampus proper, are damaged. Data from the present study are consistent with these findings. Moreover, while the memory test in the right hippocampus evidenced a trend toward significance among the tasks, significant differences were found only in the right hippocampus at encoding, suggesting that it may be activity in the right hippocampus proper during the encoding phase that is necessary for this particular task. Furthermore, the behavioral evidence indicates that this increased activation during the memory tasks was not due to differences in the degree of difficulty among tasks or an increase in processing time required to perform

Table 1
Mean (\pm SD) Accuracy and Reaction Time in the Button-Press Responses

Task	Phase 1		Phase 3	
	Accuracy (%)	Reaction time (s)	Accuracy (%)	Reaction time (s)
DMS	97.22 \pm 5.94	1,767.49 \pm 789.75	86.11 \pm 20.14	2,401.99 \pm 548.91
DNMS	99.31 \pm 1.96	1,737.99 \pm 774.52	87.50 \pm 16.20	2,652.72 \pm 490.05
Color count	93.06 \pm 9.27	2,162.60 \pm 927.56	89.58 \pm 9.59	3,365.92 \pm 650.97

Note. DMS = delayed matching-to-sample; DNMS = delayed nonmatching-to-sample.

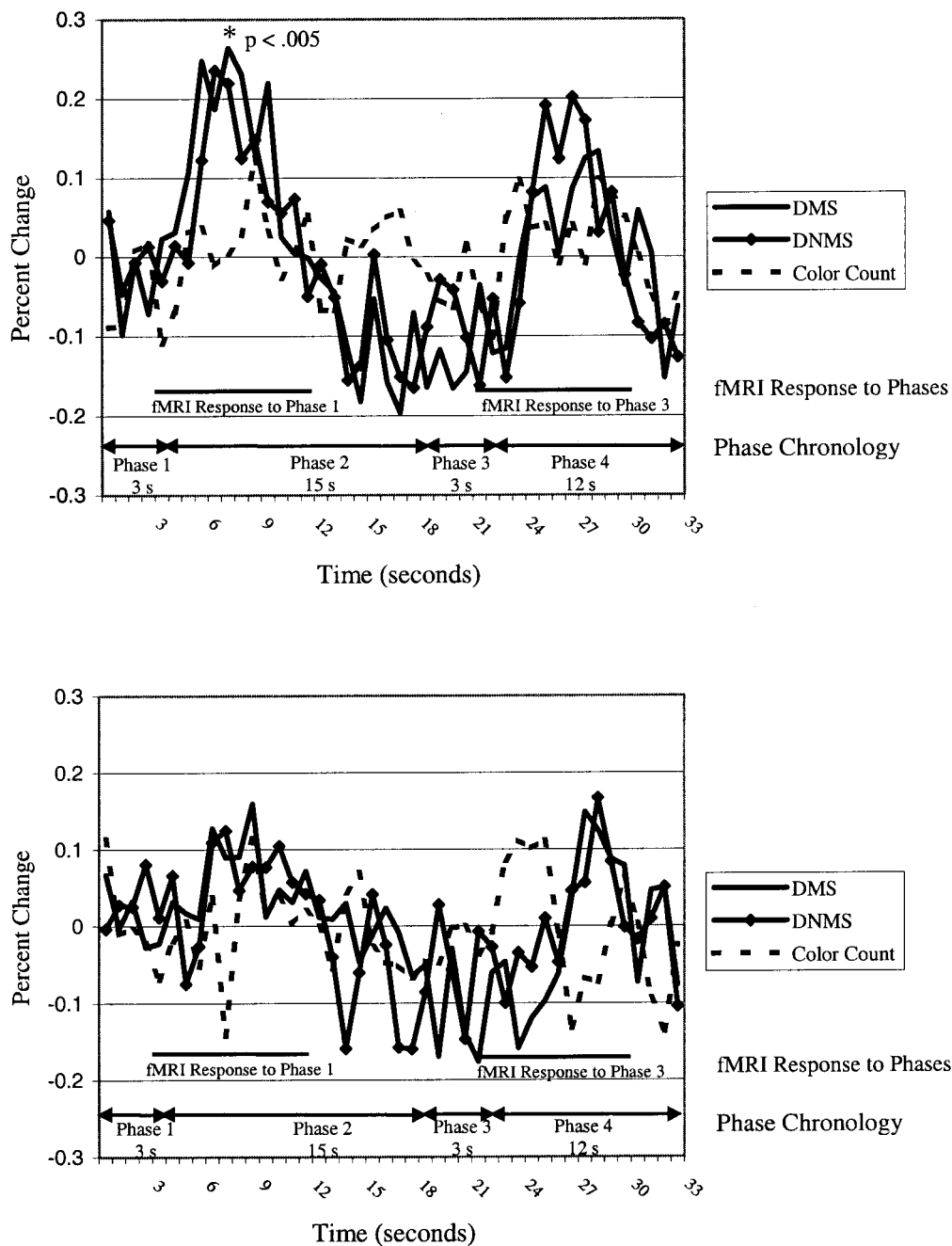


Figure 1. Activation of the right (top) and left (bottom) hippocampus in the three tasks. The graphs represent the mean blood oxygenation level-dependent (BOLD) signal for all participants across time. Phase 1 represents the encoding phase for the delayed matching-to-sample (DMS) and delayed nonmatching-to-sample (DNMS) tasks and the first color counting phase in the perceptuomotor control task. Phase 2 is the delay period, when only a fixation point is presented for all tasks. Phase 3 is the test of recognition memory for DMS and DNMS and the second color counting phase in the perceptuomotor control task. Phase 4 is the intertrial interval, when only a fixation point is presented for all tasks. The BOLD signal exhibits a delayed response (described in the introduction and in the Method section). In particular, the BOLD signal commences approximately 3 s after stimulus onset and resolves within 12 s. The range for determining the possible peak response for each participant is depicted in the line above fMRI Response to Phase 1 and in the line above fMRI Response to Phase 3. The peak for each participant within each task, phase, and hemisphere was used as the midpoint of the window; the mean activation for analysis was derived from each window. fMRI = functional magnetic resonance imaging.

the memory tasks. No statistical differences were found among the three tasks in performance. Moreover, button press latencies were comparable in the first phase (encoding) of the three tasks, and the latency for the color counting task was even longer than the latency in either memory task in the second phase. Finally, the time course of the BOLD response for Phase 1 (encode for DNMS and DMS and color count for control) and Phase 3 (memory test for DNMS and DMS and color count for control) was comparable to previous investigations (Buckner, 1998; Janz et al., 2000). The BOLD response began approximately 3 s following stimulus onset, peaked between 6–8 s, and resolved within 11–12 s.

The finding that the hippocampus was significantly active during the encoding phase is consistent with other studies that have examined the role of the hippocampus in memory. Specifically, the encoding of novel stimuli during the learning phase of an artificial grammar system led to greater hippocampal activation (Dolan & Fletcher, 1999; Strange, Fletcher, Henson, Friston, & Dolan, 1999). Similarly, Stern et al. (1996) presented novel as well as repeated stimuli to participants and found that novel stimuli elicited greater hippocampal activation. Successful encoding of words (i.e., words that were later correctly recalled) correlated with activity in the posterior hippocampus (Fernández et al., 1998). Finally, event-related potentials were measured within the hippocampus as participants encoded words for later recall; the waveforms were larger for words that were remembered relative to words that were forgotten (Fernández et al., 1999).

In the present study, why did memory processing lead to greater activation in the right hippocampus and not in the left? Studies examining memory function in the MTL have found that the type of stimulus often leads to laterality effects. The presentation of novel letter strings during the learning of an artificial grammar system leads to activation in the left anterior hippocampus (Strange et al., 1999). Martin, Wiggs, and Weisberg (1997) presented real and nonsense objects, as well as real and nonsense words, to participants and found greater response in the right MTL for both types of objects over both types of words. Similarly, in another study, face encoding led to greater activation in the right MTL, whereas word encoding elicited greater response in the left hippocampus (Kelley et al., 1998). In contrast, an fMRI study that used the same task and stimuli as the present one found left but not right hippocampal activation (Elliott & Dolan, 1999). This finding was revealed when activation during the short delay (5 s) was subtracted from activation in the long delay (15 s). In this study, a block design was used, so it is not possible to determine which aspect(s) of the task (encoding, delay, or test) led to the differential response. Because we did not find activation in the left hippocampus, it is possible that differences in the comparison tasks between the two studies account for the discrepant results. In particular, Elliott and Dolan's findings may reflect a priming mechanism, whereby the higher rate of repetition of the repeated stimuli caused suppression of the hippocampal response. Research using event-related fMRI with these tasks at different delays would help clarify the discrepant results.

Turning to evidence from neuropsychological research on laterality, damage to the left temporal lobe leads to impairments in verbal memory (e.g., Meyer & Yates, 1955; Milner, 1972). In contrast, right temporal lobe damage is associated with deficits in memory for visual patterns and objects (e.g., Kimura, 1963; Milner, 1968; Pigott & Milner, 1993). However, in a study with brain-damaged patients, in which stimuli comparable to those used

in this study were used, a small sample size precluded statistical analyses, but no trend in the effects of laterality was reported (Owen et al., 1995).

The results from the present study clarify other fMRI findings in which the level-of-processing framework was used, whereby more deeply processed stimuli are remembered better than stimuli that are processed shallowly (Craik & Lockhart, 1972). For example, words that are semantically encoded are better remembered than words in which the number of t-junctions are counted. The tasks in the present study are comparable to those in which this framework was used: DMS and DNMS require deep processing, whereas counting colors involves shallow processing. Kelley et al. (1998) used this framework with fMRI. They asked participants to encode words, faces, and objects for a subsequent test of memory (deep processing) and also presented comparable stimuli, which participants were requested to passively view (shallow processing). Active memory encoding increased MTL response relative to passive viewing. (The hippocampus proper was not reported.) Moreover, in a positron emission tomography study using the depth-of-processing framework, participants were presented with words. The participants were asked to determine whether each word referred to something living (deep processing) in one scan session and to decide if the letter *a* appeared in each word (shallow processing) in the other scan (Kapur, Tulving, Wilson, Houle, & Brown, 1994). No MTL activation was found when the activation in the *a* counting task was subtracted from the activation in the semantic task. The MTL may have been activated in both tasks and, while the semantic encoding led to more pronounced MTL activation, the positron emission tomography lacked the sensitivity to detect this difference (Martin, 1999). Results from the present study are consonant with this suggestion. The hippocampus showed some activation in response to the perceptuomotor task (see Figure 1), but the memory tasks led to greater activation during the encoding phase in the right hippocampus. Thus, the depths to which stimuli are processed may modulate activity in the hippocampus.

Furthermore, an event-related approach in which particular structures are targeted may be more sensitive for neurophysiologically differentiating between levels of processing than the block design with whole-brain image acquisition. In one fMRI study, participants decided whether presented words were abstract or concrete (deep processing) in one scan session and uppercase or lowercase in another (shallow processing; Wagner et al., 1998). Although activation was revealed in the hippocampus when comparing deep processing to viewing a fixation point, no activation within the hippocampal region was found in the comparison of deep versus shallow processing. Similarly, in Elliott and Dolan (1999), hippocampal activation was not found in a comparison of DMS and DNMS tasks versus a perceptuomotor control. Both of these studies acquired whole-brain images, and a block design was used in the latter study. In the present study we used event-related fMRI and selectively imaged the hippocampus, permitting the monitoring of the structure at a higher frequency. Whereas whole-brain image acquisition allows for the measurement of entire neural circuits, the approach in the present study may provide a more sensitive measure of hippocampal function.

References

- Alvarez, P., Zola-Morgan, S., & Squire, L. R. (1995). Damage limited to the hippocampal region produces long-lasting memory impairment in monkeys. *Journal of Neuroscience*, *15*, 3796–3807.

- Buckner, R. L. (1998). Event-related fMRI and the hemodynamic response. *Human Brain Mapping, 6*, 373–377.
- Cohen, J. D., MacWhinney, B., Flatt, M., & Provost, J. (1993). PsyScope: A new graphic interactive environment for designing psychology experiments. *Behavioral Research Methods, Instruments, and Computers, 25*, 257–271.
- Correll, R. E., & Scoville, W. B. (1965). Performance on delayed match following lesions of medial temporal lobe structures. *Journal of Comparative Physiology and Psychology, 60*, 360–367.
- Craik, F. I. M., & Lockhart, R. S. (1972). Levels of processing: A framework for memory research. *Journal of Verbal Learning and Verbal Behavior, 11*, 268–294.
- Dolan, R. J., & Fletcher, P. F. (1999). Encoding and retrieval in human medial temporal lobes: An empirical investigation using functional magnetic resonance imaging (fMRI). *Hippocampus, 9*, 25–34.
- Duvernoy, H. M. (1991). *The human brain surface: Three-dimensional sectional anatomy and MRI*. New York: Springer.
- Elliott, R., & Dolan, R. (1999). Differential neural responses during performance of matching and nonmatching to sample tasks at two delay intervals. *Journal of Neuroscience, 19*, 5066–5073.
- Fernández, G., Arndt, E., Grunwald, T., Pezer, N., Lehnertz, K., Dumpelmann, M., et al. (1999, September 3). Real-time tracking of memory formation in the human rhinal cortex and hippocampus. *Science, 285*, 1582–1585.
- Fernández, G., Weyerts, H., Schrader-Bolsche, M., Tendolker, I., Smid, H. G., Tempelmann, C., et al. (1998). Successful verbal encoding into episodic memory engages the posterior hippocampus: A parametrically analyzed functional magnetic resonance imaging study. *Journal of Neuroscience, 18*, 1841–1847.
- Fray, P. J., Robbins, T. W., & Sahakian, B. J. (1996). Neuropsychiatric applications of CANTAB. *International Journal of Geriatric Psychiatry, 11*, 329–336.
- Friedman, H., & Goldman-Rakic, P. S. (1988). Activation of the hippocampus and dentate gyrus by working memory: A 2-deoxyglucose study of behaving rhesus monkeys. *Journal of Neuroscience, 8*, 4693–4706.
- Gabrieli, J. D. E. (1998). Cognitive neuroscience of human memory. *Annual Review of Psychology, 49*, 87–115.
- Gaffan, D. (1974). Recognition impaired and association intact in the memory of monkeys after transection of the fornix. *Journal of Comparative and Physiological Psychology, 86*, 1100–1109.
- Janz, C., Schmitt, C., Speck, O., & Hennig, J. (2000). Comparison of the hemodynamic response to different visual stimuli in single-event and block stimulation fMRI experiments. *Journal of Magnetic Resonance Imaging, 12*, 708–714.
- Kapur, S., Tulving, E., Wilson, A. A., Houle, S., & Brown, G. M. (1994). Neuroanatomical correlates of encoding in episodic memory: Levels of processing effect. *Proceedings of the National Academy of Sciences, USA, 91*, 2008–2011.
- Kelley, W. M., Miezin, F. M., McDermott, K. B., Buckner, R. L., Raichle, M. E., Cohen, N. J., et al. (1998). Hemispheric specialization in human dorsal frontal cortex and medial temporal lobe for verbal and nonverbal memory encoding. *Neuron, 20*, 927–936.
- Kimura, D. (1963). Right temporal-lobe damage: Perception of unfamiliar stimuli after damage. *Archives of Neurology, 8*, 264–271.
- Mahut, H., & Cordeau, J.-P. (1963). Spatial reversal deficit in monkeys with amygdala-hippocampal ablations. *Experimental Neurology, 7*, 426–434.
- Mahut, H., Zola-Morgan, S., & Moss, M. (1982). Hippocampal resections impair associative learning and recognition memory in the monkey. *Journal of Neuroscience, 2*, 1214–1229.
- Martin, A. (1999). Automatic activation of the medial temporal lobe during encoding: Lateralization influences of meaning and novelty. *Hippocampus, 9*, 62–70.
- Martin, A., Wiggs, C. L., & Weisberg, J. (1997). Modulation of human medial temporal lobe activity by form, meaning, and experience. *Hippocampus, 7*, 587–593.
- Meyer, V., & Yates, A. J. (1955). Intellectual changes following temporal lobectomy for psychomotor epilepsy. *Journal of Neurology, Neurosurgery and Psychiatry, 18*, 44–52.
- Milner, B. (1968). Visual recognition and recall after right temporal-lobe excision in man. *Neuropsychologia, 6*, 191–209.
- Milner, B. (1972). Disorders of learning and memory after temporal lobe lesions in man. *Clinical Neurosurgery, 19*, 421–446.
- Mishkin, M., & Delacour, J. (1975). An analysis of short-term visual memory in the monkey. *Journal of Experimental Psychology: Animal Behavioral Processes, 1*, 326–334.
- Murray, E. A., & Mishkin, M. (1998). Object recognition and location memory in monkeys with excitotoxic lesions of the amygdala and hippocampus. *Journal of Neuroscience, 18*, 6568–6582.
- Orbach, J., Milner, B., & Rasmussen, T. (1960). Learning and retention in monkeys after amygdala-hippocampus resection. *Archives of Neurology, 3*, 230–251.
- Owen, A. M., Sahakian, B. J., Semple, J., Polkey, C. E., & Robbins, T. W. (1995). Visuo-spatial short-term recognition memory and learning after temporal lobe excisions, frontal lobe excisions or amygdalo-hippocampectomy in man. *Neuropsychologia, 33*, 1–24.
- Pigott, S., & Milner, B. (1993). Memory for different aspects of complex visual scenes after unilateral temporal- or frontal-lobe resection. *Neuropsychologia, 31*, 1–15.
- Sahakian, B. J., & Owen, A. M. (1992). Computerized assessment in neuropsychiatry using CANTAB. *Journal of the Royal Society of Medicine, 85*, 399–402.
- Scoville, W. B., & Milner, B. (1957). Loss of recent memory after bilateral hippocampal lesions. *Journal of Neurology, Neurosurgery and Psychiatry, 20*, 11–21.
- Stern, C. E., Corkin, S., Gonzalez, R. G., Guimaraes, A. R., Baker, J. R., Jennings, P. J., et al. (1996). The hippocampal formation participates in novel picture encoding: Evidence from functional magnetic resonance imaging. *Proceedings of the National Academy of Sciences, USA, 93*, 8660–8665.
- Strange, B. A., Fletcher, P. C., Henson, R. N. A., Friston, K. J., & Dolan, R. J. (1999). Segregating the functions of the human hippocampus. *Proceedings of the National Academy of Sciences, USA, 96*, 4034–4039.
- Strupp, J. P. (1997). STIMULATE: A GUI-based fMRI analysis software package. *NeuroImage, 3*(Suppl.), S607.
- von Bechterew, W. (1900). Demonstration eines Gehirns mit Zerstörung der vorderen und inneren Teile der Hirnrinde beider Schläfenlappen [Demonstration of a brain with lesions of the anterior and inner parts of the temporal lobes]. *Neurologisches Zentralblatt, 19*, 990–991.
- Wagner, A. W., Schacter, D. L., Rotte, M., Koutstaal, W., Maril, A., Dale, A. M., et al. (1998, August 21). Building memories: Remembering and forgetting of verbal experiences as predicted by brain activity. *Science, 281*, 1188–1190.
- Zola, S. M., Squire, L. R., Teng, E., Stefanacci, L., Buffalo, E. A., & Clark, R. E. (2000). Impaired recognition memory in monkeys after damage limited to the hippocampal region. *Journal of Neuroscience, 20*, 451–463.
- Zola-Morgan, S., Squire, L. R., & Amaral, D. G. (1986). Human amnesia and the medial temporal region: Enduring memory impairment following a bilateral lesion limited to field CA1 of the hippocampus. *Journal of Neuroscience, 6*, 2950–2967.
- Zola-Morgan, S., Squire, L. R., Rempel, N. L., Clower, R. P., & Amaral, D. G. (1992). Enduring memory impairment in monkeys after ischemic damage to the hippocampus. *Journal of Neuroscience, 12*, 2582–2596.