



Health conditions of Guiana dolphins facing cumulative anthropogenic impacts

Estela Dibo Soares^{1,2} · Mauricio Cantor^{2,3,4,5,6} · Ana Paula Frederico Rodrigues Loureiro Bracarense⁷ · Kátia Regina Groch⁸ · Camila Domit^{1,2}

Received: 7 December 2021 / Accepted: 4 August 2022 / Published online: 11 October 2022
© The Author(s) 2022

Abstract

Coastal areas are associated with anthropogenic activities and stressors that can expose the marine fauna to negative cumulative impacts. Apex predators, such as dolphins, can flag the quality of their environment through health parameters such as cutaneous and body conditions. We examined the potential relationship between environmental conditions and health parameters of Guiana dolphins around a port and a conservation unit within the Paranaguá Estuarine Complex, southern Brazil. During boat surveys between July 2018 and April 2019 covering both areas, we measured environmental parameters, photographed dolphins to infer their health condition and the frequency of use of the estuary. In total, 204 individual Guiana dolphins were photo-identified, 52 of which were seen in both years. In general, dolphins showed poor body condition (76% classified as emaciated or thin in 2018, and 79% in 2019), diverse cutaneous conditions (four types of lesions suggestive of an infectious aetiology, two conditions suggestive of traumatic events of anthropogenic origin, and two anomalous pigmentation) and a high prevalence of such cutaneous conditions (85% in 2018, 70% in 2019). Most individuals maintained their body and cutaneous conditions between the two years. There were no clear differences between the port and the conservation areas in terms of environmental conditions, frequency of use and health conditions of individual dolphins, suggesting that dolphins inhabiting this estuarine complex are exposed to potential cumulative impacts, such as pollutants, noise and habitat degradation. This study provides baseline information on some health parameters of Guiana dolphins in southern Brazil and highlights the need for systematic, long-term health assessment of Guiana dolphin populations to guide conservation actions to safeguard this vulnerable species.

Keywords Anthropogenic stressors · Coastal cetaceans · Health assessment · Cutaneous lesions · Emaciation · Port · Conservation unit · *Sotalia guianensis*

Mauricio Cantor and Camila Domit have shared co-senior authorship.

Handling editors: Stephen C.Y. Chan and Leszek Karczmarski.

This article is a contribution to the special issue on “Individual Identification and Photographic Techniques in Mammalian Ecological and Behavioural Research – Part 2: Field Studies and Applications” — Editors: Leszek Karczmarski, Stephen C.Y. Chan, Scott Y.S. Chui and Elissa Z. Cameron

✉ Estela Dibo Soares
esteladsoares@gmail.com

✉ Mauricio Cantor
mauricio.cantor@oregonstate.edu

Extended author information available on the last page of the article

Introduction

Coastal areas are typically productive environments that harbour a high biodiversity (Crossland et al. 2006) and attract human populations which are responsible for urban development and for industrial, port and agricultural activities (Halpern et al. 2008). Port areas are highly modified environments with heavy marine traffic and persistent dredging and piling activities that can generate cumulative negative impacts on the marine fauna, such as habitat loss, noise and chemical pollution (Grech et al. 2013; Todd et al. 2015). In the southwestern Atlantic Ocean, the Paranaguá Estuarine Complex is a world heritage site that includes one of the most productive estuarine areas in southern Brazil and an intensely urbanised port area (see Possatto et al. 2016). This estuarine complex is home to a large population (1371–2393

individuals; Domit et al. 2021) of Guiana dolphins (*Sotalia guianensis*, Fig. A1), an endemic coastal dolphin that is considered an environmental sentinel (Kajiwara et al. 2004; Van Bresseem et al. 2009a; Lailson-Brito et al. 2010; Moura et al. 2014; Domit et al. 2021).

Throughout their distribution, Guiana dolphins are exposed to several human activities. Off the Brazilian coast, for instance, they are often threatened by vessel collision (Domiciano et al. 2016), entanglement and incidental mortality in fishing gear (Moura et al. 2014; Domiciano et al. 2016), bioaccumulation of chemical compounds (Dorneles et al. 2008, 2020; Lailson-Brito et al. 2010; Vidal et al. 2020; Manhães et al. 2021; Trevizani et al. 2021), and exposure to emerging diseases (Sacristán et al. 2018; Sanchez-Sarmiento et al. 2019; Groch et al. 2020). These cumulative anthropogenic impacts may cause injuries (Domiciano et al. 2016) and health disorders, such as immune depression (Moura et al. 2014; Domiciano et al. 2016; Manhães et al. 2021), poor body condition (Reif et al. 2009; Van Bresseem et al. 2009a, b; Domiciano et al. 2016), a higher prevalence of skin lesions and infectious diseases (Van Bresseem et al. 2009a; Groch et al. 2014; Seade et al. 2017; Sacristán et al. 2018). Declines in individual health can affect population size and resilience (e.g. Azevedo et al. 2017). For example, in 2018, an epizootic event of cetacean morbillivirus caused emaciation and high mortality in Guiana dolphins from Rio de Janeiro state (Groch et al. 2018, 2020; Flach et al. 2019; Cunha et al. 2021). Moreover, a high overlap with fishing activities results in injury and mortality through bycatch (Azevedo et al. 2009; Domiciano et al. 2016). As a consequence, this species is classified as “Near Threatened” by the IUCN (Secchi et al. 2019) and considered a conservation priority by the International Whaling Commission (IWC) (Van Bresseem et al. 2009a; Domit et al. 2021), and by the National Action Plan for Conservation of Aquatic Mammals in Brazil (Barreto et al. 2011).

In the Paranaguá Estuarine Complex, Guiana dolphins are found year-round, feeding and breeding (Domit 2010; Santos et al. 2010; Bonin et al. 2017; Moura et al. 2021), even in noisy and degraded areas. The exposure to human activities might be counterbalanced by high prey availability, as Guiana dolphins are often observed using the side of anchored ships in ports as a barrier to corral and capture fish (Domit 2010). Although apparently beneficial in the short term, the daily exposure to such environments may lead to long-term consequences, which can be manifested by disruption of behaviour (Bittencourt et al. 2017), poor body condition, and the presence of cutaneous conditions (Van Bresseem et al. 2009a). The Guiana dolphins living near the port of Paranaguá a decade ago showed more cutaneous alterations than a population living in a relatively pristine area (Cananéia estuary; Van Bresseem et al. 2009a). Such

altered cutaneous conditions were considered indications of depression of the immunological system and increased susceptibility to infections (Van Bresseem et al. 2009a; Domiciano et al. 2016).

Cutaneous alterations and body condition are often evident in cetaceans and can be effectively detected by photographing individual animals (Thompson and Hammond 1992; Wilson et al. 1999; Van Bresseem et al. 2009a; Christiansen et al. 2020). Here, we evaluate the potential relationship between the health status and environmental conditions by comparing the cutaneous and body conditions of individual Guiana dolphins that use two areas within the Paranaguá Estuarine Complex: one with high anthropogenic activity surrounding a port, and another with low anthropogenic activity surrounding a conservation unit. We hypothesise that dolphins seen more often in and around the port have higher occurrence and prevalence of skin lesions and poorer body conditions than those seen more often at the conservation unit.

Methods

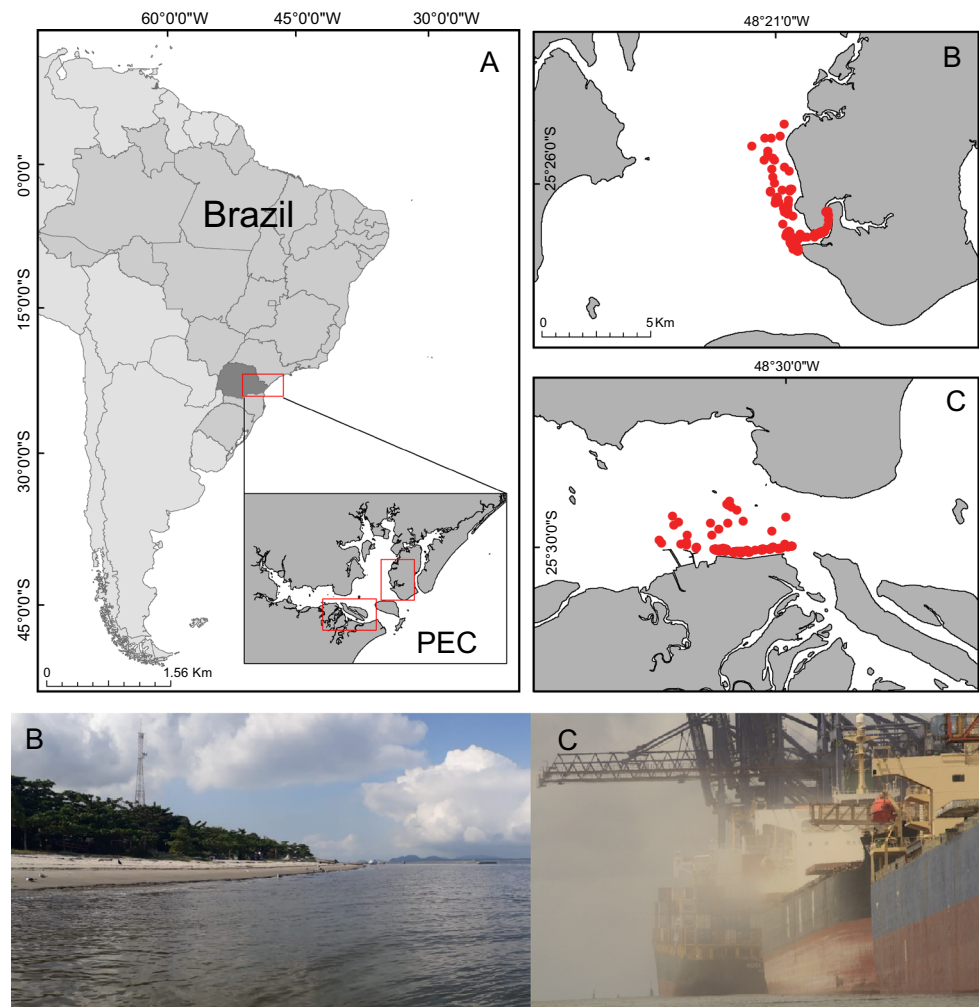
Study area

The study was carried out in two sectors of the Paranaguá Estuarine Complex, southern Brazil (Fig. 1A): adjacent to the Ilha das Peças island (IP, Fig. 1B; 25° 27' S; 48° 20' W) and surrounding the Paranaguá Port Complex (PPC, Fig. 1C; 25° 30' S; 48° 32' W). These sectors are continuously used by Guiana dolphins and were chosen for their differences in the diversity and intensity of anthropogenic activities with potential impact on marine life. The port, located in Paranaguá Bay, is the second-largest port in Brazil. Its sector include a ship manoeuvring stretch, mooring berths, public wharves, and wharves of liquid and flammable bulk (Soares and Lamour 2008). Dredging for maintenance or deepening of mooring berths, expansion of the port terminal and vessel traffic are continuous at port (Soares and Lamour 2008; Barletta et al. 2016). The Ilha das Peças island is part of the Superagui National Park, a federal conservation unit. Although the island sector is a protected area, it includes some aquatic anthropogenic activities such as artisanal fishing and tourism and is only 40 km far from the port (Abreu et al. 2017).

Data sampling

A total of 44 daily boat-based surveys were carried out between July 2018 and April 2019, alternating sectors each week. The sampling days were determined by the weather, tide condition and navigation safety. The port sector was

Fig. 1 A Paranaguá Estuarine Complex (PEC), Paraná, southern Brazil, where the B Ilha das Peças (IP) and C Paranaguá Port Complex (PPC) are located. Red circles indicate sightings of Guiana dolphins in 2018 and 2019



sampled using a strip transect 11 km long and 1 km broad (Fig. 1C) whilst the island sector was sampled with a 12 km by 1 km transect (Fig. 1B). Transects were covered searching for groups of Guiana dolphins, here defined as individuals seen in proximity and engaged in the same behavioural state, which could vary from two to hundreds of individuals. The size and composition of the groups were recorded whenever an individual joined or left the group. The GPS location of the groups was taken, and behavioural states were recorded every 5 min (e.g. Baker et al. 2017). To evaluate environmental conditions in both sectors, water parameters (salinity, transparency, and temperature) were measured hourly, and tidal conditions were retrieved from local weather stations (<http://ondas.cptec.inpe.br/>).

Individual identification and health assessment

Upon encountering a group, sequential photographs of all dolphins were taken to record the dorsal fins for individual identification (see Karczmarski et al. 2022a, b). Natural marks observed on the dorsal fins were compared to identify

individuals using a standard photo-identification protocol (Hammond et al. 1990). Animals that could not be individually identified (i.e. unmarked dorsal fin) were excluded from the analysis.

The visible body surface of the dolphins was photographed and examined for the presence of cutaneous conditions and to evaluate the body condition. For body condition, individuals were categorised as emaciated, thin or in good condition, based on the degree of atrophy of the epaxial musculature, prominence of ribs, and amount of subcutaneous fat in the nuchal region (Fig. 2; according to Pugliares et al. 2007; Joblon et al. 2014). In the “emaciated” category, the ribs are more apparent and a greater concavity can be observed in the latero-dorsal region and in the neck, due to loss of fat deposits and muscle mass; in the “thin” category, a moderate concavity can be observed in the latero-dorsal region of the animal and in the neck; in the “good condition” category, the latero-dorsal region of the body and the neck have a flat or convex appearance (Pugliares et al. 2007; Joblon et al. 2014).

The cutaneous conditions were identified by comparing the images collected in the field with descriptions found in scientific articles from a systematic review of the literature (examples in Table 1; Fig. 3). Cutaneous conditions were classified in three categories of alterations: “lesions suggestive of an infectious aetiology” were possibly related to viral, protozoal, fungal and/or bacterial aetiology, such as lobomycosis-like disease (Van Bresse et al. 2007), nodules evoking lobomycosis-like disease (Van Bresse et al. 2009a), circular lesions and circular ulcerated lesions. The second category, “conditions suggestive of traumatic events of anthropogenic origin”, included scars that were possibly related to direct anthropogenic impacts, and may have led to deformity of dorsal fin and the dorsal region of the body, or linear indentations indicative of interaction with fishing nets. The third category, “anomalous pigmentation” included hypopigmentation and hyperpigmentation of the skin; the description, possible aetiology and references are detailed in Table 1.

The prevalence of cutaneous conditions was calculated as the ratio between the number of photo-identified individuals with a given type of cutaneous alteration and the total of photo-identified individuals (Wilson et al. 1999; Van Bresse et al. 2003; Gonzalvo et al. 2015). The same ratio was calculated for the prevalence of categories of body condition. Changes on cutaneous and body conditions were recorded for individuals observed in both years.

Frequency of use of area

The use of the Paranaguá Estuarine Complex was estimated as the proportion of days that each photo-identified individual Guiana dolphin was recorded within the estuary relative to the total of sampled days (Batista et al. 2014). The frequency of use of each sector was evaluated by the proportion between the number of months each individual was sighted in each sector in relation to the total of months sampled (Rossi-Santos et al. 2007). From this frequency, individuals were classified as resident (> 50%), transient I (25–50%) and transient II (< 25%) in each sector (adapted from Moura et al. 2021).

Data analyses

The environmental parameters were compared between sectors using, when appropriate, parametric (Student's *t*) or non-parametric (Mann–Whitney) tests. Fixed Kernel Density Estimation (fixed-KDE) was used to analyse space use and distribution patterns of Guiana dolphins in each sector. Distribution maps of groups of dolphins were made from the GPS locations and density results using software QGIS 3.10.2.

To investigate the relationship between health status and space use, a generalised linear model was built considering a Poisson error distribution and a log link function. The dependent variable was the total number of cutaneous




Fig. 2 Body condition categories of Guiana dolphins. **A** emaciated: apparent ribs, concavity below of dorsal fin with sharp dorsal edge (score 1); **B** thin: some degree of concavity below the dorsal fin (score 2); **C** good condition: rounded body (score 3)

conditions quantified per individual (the sample unit), and the independent variables were the study sector where the individual was sighted (port, island, both), the initial body condition category (suggestive of general health condition), and the frequency of use of the entire Paranaguá Estuarine Complex (estimated as the proportion between the number of days each individual was sighted in the entire area and the total number of days sampled). As a reference, a null model with only the intercept was built, and compared to the complete model using the Akaike Information Criterion for small samples (AICc; Burnham and Anderson 2002). The model was validated following the linear model evaluation protocol (Bolker et al. 2009), including inspection of Q–Q plots, presence of outliers, temporal and spatial autocorrelation, and plots of residuals against fitted data. Model validation was achieved with 1000 simulated model residuals using the *DHARMA* R package (Hartig 2020).

Table 1 Description and categories of all types of cutaneous conditions found in Guiana dolphins observed in both study sectors (Ilha das Peças—IP, Paranaquá Port Complex—PPC) of the Paranaquá Estuarine Complex, Paraná, southern Brazil

Cutaneous conditions	Description	Study sector	Possible aetiology	References	Examples
Lesions suggestive of an infectious aetiology					
Lobomycosis-like	Nodules and raised white areas with ulcers and crusts. Mainly observed in the fins, head and caudal peduncle	IP	Fungus <i>Paracoccidioides brasiliensis</i>	c.f. Simões-Lopes et al. (1993), Reif et al. (2006), Van Bresseem et al. (2007), Murdoch et al. (2008), Rotstein et al. (2009), Van Bresseem et al. (2009a) and Sacristán et al. (2017)	Figure 3A, B
Nodule	Elevation with a normally pigmented circumference shape with variable size on the animal's skin	IP, PPC	Fungi <i>Paracoccidioides brasiliensis</i> , <i>Fusarium</i> spp. and <i>Trichophyton</i> spp.; Bacterium <i>Streptococcus iniae</i> ; Papillomavirus	c.f. Kiszka et al. (2009), Van Bresseem et al. (2009a) and Yang et al. (2013)	Figure 3C, D
Circular lesions	White (E) or dark (F) circular areas or semicircles delimiting areas of discoloration in the skin. Elevated whitish (G) or greyish (H) circular areas	IP, PPC	Dermatitis caused by infectious agents or parasites. It can be aggravated by environmental conditions	c.f. Leone et al. (2019)	Figure 3E–H
Circular ulcerated lesions	Round whitish ulcerated area showing a delimited edge	PPC	Unknown aetiology	c.f. Sanino et al. (2014)	Figure 3I, J
Conditions suggestive of traumatic event of anthropogenic origin					
Scars leading to deformity of dorsal fin	Dorsal fin area without evidence of cut and with irregular edge	IP	Undetermined cause	c.f. Leone et al. (2019) and Chan and Karczmariski (2019)	Figure 3K
Indicative of interaction with fishing net	Deep cut and linear marks, possibly caused by fishing net	IP	Anthropogenic activity	c.f. Baird and Gorgone (2005), Kiszka et al. (2008), Domiciano et al. (2016) and Townsend and Staggs (2021)	Figure 3L, M
Anomalous pigmentation					
Hypo pigmentation of the skin	Whitish areas in the skin showing aleatory shape and no delimitation	PPC	Trauma, scarring, infection, changes in environment, toxins	c.f. Chabanne et al. (2012) and Townsend and Staggs (2021)	Figure 3N
Hyper pigmentation of the skin	Darker area in relation to the skin, without the presence of a light border. Blackened areas in the skin showing random shape and no delimitation	PPC	Undetermined cause	c.f. Chabanne et al. (2012)	Figure 3O




Fig. 3 Examples of cutaneous conditions found in Guiana dolphins of Paranaguá Estuarine Complex, Paraná, southern Brazil (see Table 1)

Table 2 Number of individual Guiana dolphins with body condition scores in each study sector (Ilha das Peças—IP, Paranaguá Port Complex—PPC) of the Paranaguá Estuarine Complex, Paraná, southern Brazil

Study sector	Score timing	Body condition score			Total
		1—emaciated	2—thin	3—good	
Total	Initial score	17 (25%)	34 (51%)	16 (24%)	67
	Final score	18 (27%)	35 (52%)	14 (21%)	67
Paranaguá Port Complex	Initial score	9 (27%)	15 (44%)	10 (29%)	34
	Final score	8 (23%)	20 (59%)	6 (18%)	34
Ilha das Peças island	Initial score	13 (24.5%)	27 (51%)	13 (24.5%)	53
	Final score	16 (30%)	26 (49%)	11 (21%)	53

Results

During the 44 days of survey, 204 groups were sighted and 204 Guiana dolphins were identified, of which 52 individuals were seen in the both years. Most of these dolphins (59%) were seen exclusively around the island; 31% were seen exclusively around the port, and the remainder was seen in both sectors (10%). The groups were generally composed of adults (197/204; 97%) and rarely included calves (only 45/204; 22%). The average group size was similar in both locations: 10.22 ± 10.19 SD individuals around the island, 10.05 ± 6.90 SD around the port. Foraging was the most frequent behaviour in both the port (86.5%, 371 out of 429 events) and island sectors (77.6%, 378/487); other less frequent behaviours included displacement and socialising. The fixed-KDE maps for each sector suggested greater use of the mooring berths of bulk carriers in the port (Fig. A3a), and of the river mouth in the island (Fig. A3b). In the island, 85% (120/141) of the individuals were classified as transient II, 13% (18/141) as transient I and 2% (3/141) as resident, whilst in the port 78% (65/83) were classified as transient II, 10% (8/83) as transient I and 12% (10/83) as resident. The measured environmental conditions were not different between the sectors (salinity: $t = -1.4616$, $p = 0.1449$, $df = 303$; water transparency: $t = 0.1335$, $p = 0.8939$, $df = 270.73$; water temperature: $p = 0.6159$; $W = 7513$).

Body condition

Combining both study sectors within the entire Paranaguá Estuarine Complex, 67 individuals were repeatedly sighted and had their initial and final body conditions scored. The period between initial and final scores for most dolphins (63 individuals) ranged between one and nine months (average = 4.0 months \pm 2.5 SD), whilst four individuals had their initial and final body condition scored less than one month apart (Table S1). Nearly half of the individuals were classified as “thin” both in the initial (51%; 34/67) and in the final assessment (52%; 35/67); and about a quarter of the individuals were classified as emaciated in the initial (25%; 17/67) and final assessments (27%; 18/67); (Table 2; Table S1). Most dolphins maintained their initial body condition between the years (42%; 28/67), whilst 30% (20/67) decreased and 28% (19/67) improved their body condition score between years (Table S2).

Cutaneous conditions

In total, eight types of cutaneous conditions were identified (Tables 1, 3; Fig. 3). At least one type of cutaneous condition was observed in 68% (139/204) of the photo-identified individual dolphins in the Paranaguá Estuarine Complex, and in all 52 individuals sighted in both years. Amongst the 204 dolphins, 103 (50%) had cutaneous lesions suggestive of infectious

Table 3 Prevalence of cutaneous conditions in Guiana dolphins of the Paranaguá Estuarine Complex (PEC), Paraná, southern Brazil, by study sector and year

Category	Cutaneous conditions	PPC	IP	PEC 2018	PEC 2019	PEC total
Lesions suggestive of an infectious aetiology	Lobomycosis-like	3 (4%)	5 (3%)	5 (6%)	5 (3%)	6 (3%)
	Nodule	23 (28%)	27 (19%)	29 (33%)	38 (23%)	43 (21%)
	Circular lesion	40 (48%)	59 (42%)	39 (44%)	74 (44%)	82 (40%)
	Circular ulcerated lesion	0 (0%)	2 (1%)	1 (1%)	2 (1%)	2 (1%)
Conditions suggestive of traumatic event of anthropogenic origin	Scars leading to deformity of dorsal fin	1 (1%)	1 (0.7%)	2 (2%)	1 (1%)	2 (1%)
	Indicative of interaction with fishing net	4 (5%)	12 (8%)	9 (10%)	13 (8%)	13 (6%)
Anomalous pigmentation	Hypopigmentation of the skin	11 (13%)	10 (7%)	12 (13%)	14 (8%)	17 (8%)
	Hyperpigmentation of the skin	46 (55%)	60 (43%)	65 (73%)	70 (42%)	90 (44%)
	Number of photo-identified dolphins	83	141	89	167	204

A total of 204 individuals were photo-identified, 20 of which were sighted in both sectors, and 52 in both years. Prevalence of cutaneous conditions is shown by the number and percentage of individual dolphins sighted exclusively in a sector (Ilha das Peças—IP, Paranaguá Port Complex—PPC) in both years, the entire estuary per year (2018, 2019) and in both years (total). Note that individuals can have more than one type of lesion

aetiology, 15 (7%) presented conditions suggestive of traumatic events of anthropogenic origin and 92 (45%) had anomalous pigmentations. The prevalence of cutaneous conditions by year was 85% (76/89) in 2018 and 67% (112/167) in 2019.

Amongst the cutaneous lesions suggestive of infectious aetiology, circular lesions (40%, 82/204) and nodules (21%, 43/204) were the most prevalent in both, the port and the island sectors (Table 3). Lobomycosis-like disease and circular ulcerated lesion were also observed but only in a few individuals (3%, 6/204) and (1%, 2/204), respectively (Table 3). Amongst conditions suggestive of traumatic events of anthropogenic origin, interactions with fishing nets were the most frequent for the animals of port sector (5%, 4/83) and for the animals in the island sector (8%, 12/141), respectively (Table 3). Among the category of anomalous pigmentation, hyperpigmentation of the skin was commonly observed in dolphins from the port sector (55%, 46/83) and in the island sector (43%, 60/141), respectively (Table 3).

The cutaneous conditions representing anomalous pigmentation were the most prevalent in Paranaguá Estuarine Complex in 2018 (86%) and in 2019 (50%), followed by lesions suggestive of an infectious aetiology (83% in 2018 and 71% in 2019) and conditions suggestive of traumatic event of anthropogenic origin (12% in 2018 and 8% in 2019). The most frequent skin conditions in the entire Paranaguá Estuarine Complex by year were hyperpigmentation of the skin in 2018 (73%) and in 2019 (42%), circular lesion (44% in 2018 and 44% in 2019) and nodule (33% in 2018 and 23% in 2019) (Tables 1, 3; Fig. 3).

Case study: regression of a nodular lesion

The progression and regression to complete resolution of a nodular lesion in individual #8 were recorded. This individual was sighted more often (77.78%) around the port, and was first sighted on 31 July 2018. It was photographed with a nodular lesion on 5 September 2018 and on 19 September 2018 several whitish and slightly raised skin lesions had developed on the back and close to the dorsal fin, a condition that evoked lobomycosis-like disease (Van Bresse et al. 2009a). The lesion extended multifocally to adjacent areas until 25 September 2018. On 12 November 2018, similar cutaneous nodules were observed close to the dorsal fin with white discoloration in the area. On 5 December 2018, lesions were observed close to the tail stock. On 14 January, 21 January, 25 February and 24 April 2019, the nodular lesions were no longer seen (Fig. A2).

Space use and health status

Amongst all 139 photo-identified individual dolphins that had at least one type of cutaneous condition, 74% were classified as transient II, 17% as transient I, and 9% as resident

to the larger Paranaguá Estuarine Complex. The occurrence of lesions in Guiana dolphins that are suggestive of infectious aetiology, conditions suggestive of traumatic events of anthropogenic origin and anomalous pigmentation related to the overall frequency of use of the whole Paranaguá Estuarine Complex, independently of the study sector where the individuals were seen more often (Fig. 4). The generalised linear model ($Lesions \sim body\ condition + frequency\ of\ use\ of\ entire\ estuary + study\ sector$) suggested that the occurrence of cutaneous conditions increased with the frequency of use of the entire estuary ($\beta = 0.06$, $SE = 0.0099$, $p < 0.001$; Fig. 4A). Both the effects of body condition (thin: $\beta = -0.04$, $SE = 0.18$, $p = 0.817$; good: $\beta = -0.13$, $SE = 0.21$, $p = 0.521$) and location (island: $\beta = -0.23$, $SE = 0.21$, $p = 0.277$; port: $\beta = -0.19$, $SE = 0.21$, $p = 0.369$) were very small and not significant (Fig. 4B, C). The model had more support than the null model ($\Delta AICc = 45.13$), and showed sufficient explanatory power (adjusted $R^2 = 26.92\%$). There was no over-dispersion (observed/simulate = 0.956, $p = 0.508$), outliers ($p = 0.343$), lack of uniformity (One-sample Kolmogorov–Smirnov test, $D = 0.038$, $p = 0.944$), or temporal (DW = 1.790, $p = 0.148$) and spatial autocorrelation (Observed = 0.0005, Expected = -0.0053, SD = 0.011, $p = 0.605$).

Discussion

Guiana dolphins from the Paranaguá Estuarine Complex, including those using the port and areas bordered by conservation units, have a poor body condition and several cutaneous conditions. We detected eight types of cutaneous conditions, including hyperpigmentation of the skin, circular lesions, lobomycosis-like disease, nodules, and indications of interaction with fishing nets. Overall, this study provides baseline information on key health conditions of Guiana dolphins from southern Brazil.

Most dolphins in the Paranaguá Estuarine Complex showed poor body condition (“emaciated” and “thin”) and presented several types of cutaneous conditions (in 139 of 204 individuals), despite their different frequency of use of the port and the conservation unit areas. The lack of difference in the health conditions between dolphins using these two sampled areas may be due to the movement of dolphins throughout the entire estuary (Moura et al. 2021) and their fluid social dynamics with frequent social associations amongst individuals (Cantor et al. 2012; see also Powell et al. 2020). Guiana dolphin populations are typically composed by a combination of mostly transient and fewer resident individuals (e.g. Cantor et al. 2012; Moura et al. 2021), and most of the individual Guiana dolphins were considered transient II during this study (85% in the island and 78% in the port). In the Paranaguá Estuarine Complex, individual variation in spatial use may be related to intraspecific competition and the environmental characteristic that influence prey dynamics and quality (e.g. Santos et al.

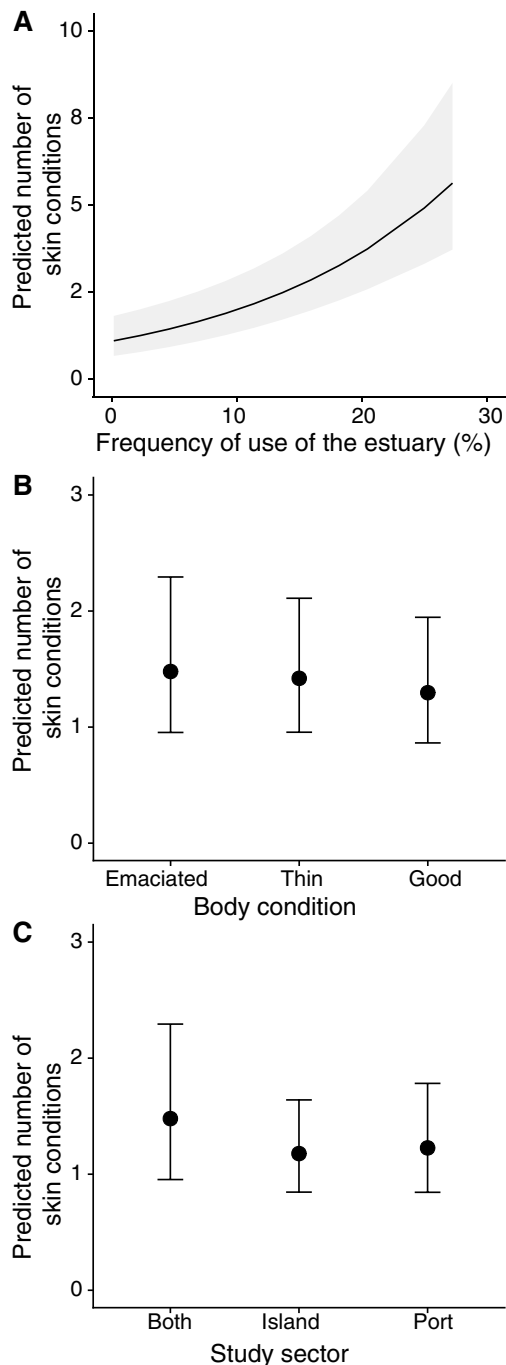


Fig. 4 The predicted number of lesions (suggestive of infectious aetiology, anomalous pigmentation, and conditions suggestive of traumatic events) in individual Guiana dolphins increases with (A) the frequency of use of the Paranaguá Estuarine Complex, Paraná, southern Brazil, but it does not change between (B) body condition categories, or (C) the study sector where the individuals were predominantly seen. Ribbons and whiskers represent 95% confidence intervals

2010; Possatto et al. 2016; Moura et al. 2021), but it can also be related to behavioural tactics and health conditions (Van Bresseem et al. 2009a; Domit 2010). Recent studies suggest

that dolphins more exposed to anthropogenic impacts have a greater chance of being severely affected by a viral epidemic than those less exposed (Collier et al. 2020; Manhães et al. 2021), possibly because of a depressed immune response and their poorer health. In addition, as other species of coastal dolphins, these dolphins may have skin lesions and lesions related to trauma caused by interactions with fishing nets or vessel collision (Chan and Karczmarski 2019). The effects of anthropogenic activities and habitat degradation on health conditions of coastal dolphins are evidenced in Hong Kong, China, where ~50% of the Indo-Pacific humpback dolphins (*Sousa chinensis*) have some form of skin lesions (Chan and Karczmarski 2019). Since emaciation has been repeatedly described in Guiana dolphins from Sepetiba Bay during and well before the morbillivirus epidemic (Van Bresseem et al. 2007; Flach et al. 2019; Groch et al. 2020), the current poor body conditions of Guiana dolphins in the Paranaguá Estuarine Complex could be an early sign for the need of managing impactful anthropogenic activities in this region to avoid worsening the health conditions of this population in the near future.

Skin lesions with a possible infectious aetiology were relatively common in the Guiana dolphins of the Paranaguá Estuarine Complex. In most cases, these lesions were characterised by a circular shape or a nodule. Whilst the exact aetiology cannot be confirmed by visual inspection alone, these types of lesions have been associated to infection by fungi *Paracoccidioides brasiliensis*, *Fusarium* sp. and *Trichophyton* sp., bacteria *Streptococcus iniae*, amongst others (Kiszka et al. 2009; Van Bresseem et al. 2009a; Yang et al. 2013). The incidence of nodules in the population decreased slightly from 33% in 2018 to 23% in 2019, but the prevalence of circular lesions remained stable from 44% in 2018 and in 2019. However, when compared to a previous assessment of this population, there was an apparent increase in the prevalence of nodules, 21% in this work from 12.6% in 2006–2007 (Van Bresseem et al. 2009a), and stability of lobomycosis-like disease (2018–2019: 3%; 2006–2007: 3.9%, Van Bresseem et al. 2009a). These findings suggest no significant improvement in health conditions in the population of the Paranaguá Estuarine Complex in more than a decade.

Moreover, we highlight that more recently, there has been increasing dredging activities, freshwater and sewage flow, and other environmental stressors in this area. Particularly, in 2018 a yearly dredging process was conducted which might have affected the highest levels and diversity of cutaneous conditions recorded, possibly due to the sediment suspension (Torres et al. 2009) and for making contaminants bioavailable throughout the food chain, thereby impacting the marine mammals (Grech et al. 2013; Todd et al. 2015). The prevalence of other types of cutaneous conditions was apparently low, especially when compared to other delphinid species. For instance, the prevalence of anomalous pigmentation in the skin of Guiana dolphins of the Paranaguá Estuarine Complex is low compared to bottlenose dolphins in Australia (Chabanne et al. 2012). However, we acknowledge that

the short duration of these studies and the high prevalence of transient dolphins do not allow long-term inferences, highlighting the need for continuous monitoring to confirm any apparent trend in prevalence of skin lesions or any other changes in cutaneous condition of this Guiana dolphin population.

The prevalence of injuries likely caused by anthropogenic activities was relatively low, with 6% of the individuals showing scars, which is suggestive of interactions with fishing nets. However, it is possible that anthropogenic interactions are underestimated because we only evaluated non-lethal interactions. Bycatch has been a major cause of death (28/30; 93%) amongst cetaceans stranded in the same studied area (Domiciano et al. 2016). Few cases of a Guiana dolphin with scars suggestive of a vessel strike are recorded in the area (Domiciano et al. 2016; Public database: <https://simba.petrobras.com.br/simba/web/>). However, no evidence of collisions was observed during the present study.

Further, the lack of difference in the health conditions of dolphins using the port and conservation areas may also be due to fishing activities and pollutants sources affecting the entire estuary (Andriquetto-Filho 1993; Lailson-Brito et al. 2010; Abreu et al. 2017; Afonso and Chaves 2021; Trevizani et al. 2021). Polychlorinated biphenyls (PCBs) and polycyclic aromatic hydrocarbons (PAHs) have been detected in the sediment and in suspended particulate material close to the port and mangrove area (Combi et al. 2013; Cardoso et al. 2016). Additionally, mercury, trace elements and other pollutants have been found accumulated throughout the food chain, including in tissues of Guiana dolphins (Lailson-Brito et al. 2010; Trevizani et al. 2019, 2021; Vidal et al. 2020). The study sector around the conservation unit, although more distant from urban, port and industrial areas, is also likely to be under the influence of pollutants that spread in the aquatic ecosystem, affecting distant areas and several trophic levels of the local food web (Combi et al. 2013; Trevizani et al. 2019). Chemical contaminants were found in the sediment across the Paranaguá Estuarine Complex, even far from the polluting source (Choueri et al. 2009).

Caveats

There is considerable evidence that the visual examination of dolphin health conditions provides an opportunity to investigate how environmental conditions and anthropogenic activities may affect dolphin populations (Van Bresseem et al. 2003, 2009a; Kiszka et al. 2009; Maldini et al. 2010; Fury and Reif 2012; Sanino et al. 2014; Gonzalvo et al. 2015; Powell et al. 2018; Leone et al. 2019; Chan and Karczmarski 2019). Combining visual inspection of body and cutaneous conditions can be a good proxy of cetacean and ecological health (Reif et al. 2009; Van Bresseem et al. 2009a; Moura et al. 2014; Bittencourt et al. 2017; Chan and Karczmarski 2019), but there are limitations. Cutaneous alterations can also occur in cetaceans due to continuous exposure to low salinity, low temperature, or to

abrupt environmental changes (Wilson et al. 1999; Duignan et al. 2020). Therefore, future studies will benefit from integrating visual monitoring with a deeper, pathological examination of cutaneous conditions to confirm their aetiology.

Similarly, although small dolphins are susceptible to changes in body mass and quick in losing bubbler mass when disturbed (Kastelein et al. 2019), body condition and bubbler thickness still provide a limited view of their overall health (Derous et al. 2020). This is because body conditions can also reflect how cetaceans interact with their physical and social environments (Wilson et al. 1999; Van Bresseem et al. 2003, 2009a; Rowe et al. 2010; Leone et al. 2019; Duignan et al. 2020). For instance, body condition may also decrease due to fluctuation in prey availability or due to higher energetic investment in mating, reproduction, lactation, and parental care (Castrillon and Bengtson Nash 2020). Therefore, it is important to carry out long-term population monitoring to develop novel approaches that can improve the accuracy of the health assessment of free-ranging dolphins.

Closing remarks

This study provides information on the relationship between spatial use and health conditions of Guiana dolphins in southern Brazil, which can inform the much-needed local actions to conserve this species (Barreto et al. 2011). The results also provide support for monitoring of body and cutaneous conditions in cetaceans, as they are proxies of health conditions that may represent noticeable short-term responses to the quality of their environment and an indicator of ecological health. Assessing health markers remains a priority for long-term population monitoring because a decline in the health of individual cetaceans can translate into reduced foraging, reproduction potential, calf development and survival (e.g. Christiansen et al. 2014, 2020), and, therefore, reduced resilience against environmental changes and population vulnerability (Choy et al. 2019).

Appendix

See Figs. A1, A2 and A3.

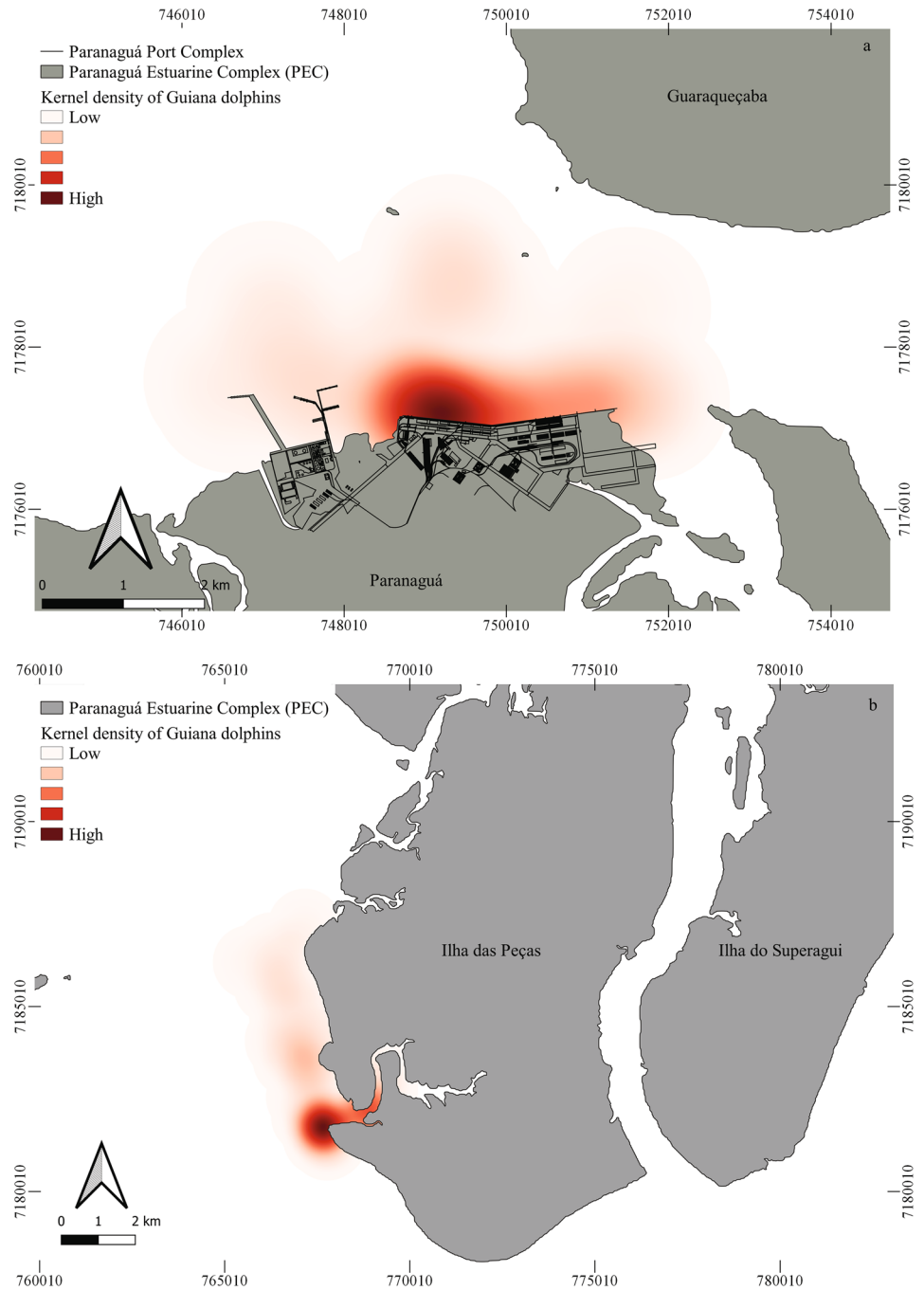


Fig. A1 Guiana dolphin, *Sotalia guianensis*, in the Paranaguá Estuarine Complex, Paraná, southern Brazil



Fig. A2 Progression and regression of a nodular lesion in the dolphin #8 recorded in the Paranaguá Estuarine Complex, Paraná, southern Brazil

Fig. A3 Kernel density map in the port region of (a) Paranaguá, Paraná, southern Brazil, where a higher concentration of Guiana dolphins can be observed near the mooring berths of bulk carriers in the port; and in (b) the island (Ilha das Peças), where a higher concentration of Guiana dolphins can be observed in the river mouth and adjacent areas



Supplementary Information The online version contains supplementary material available at <https://doi.org/10.1007/s42991-022-00299-3>.

Acknowledgements The authors are grateful to A. I. Serafim, A. Campos, J. T. Silva, G. L. Bueno, A. Correia, J. M. Santos, J. Arcega, M. J. Batista, L. R. Gama, S. P. G. Moura, L. Juraczky, A. Alvarenga, L. D. A. Silveira, C. Bernardo, A. Z. Silva, M. Santana, R. Raddatz and R. G. Ghedini for assistance with fieldwork; to S. P. G. Moura and A. Z. Silva for assistance in some analyses; and to I. G. Domiciano, S. C. Y. Chan and the anonymous reviewers for insightful comments on the manuscript. This work was supported by the Coordenação de Aperfeiçoamento de Pessoal de Nível Superior (CAPES, Brazil)

through a graduate scholarship awarded to E.D.S. (Finance Code 01), and postdoctoral fellowship awarded to M.C. (#88881.170254/2018-01). M.C. received further support from the Max Planck Institute of Animal Behavior. The photo-ID sampling was conducted under the environmental permit SISBIO/MMA 18688 (C.D.).

Authors' contributions EDS: Conceptualization, data curation, investigation, methodology, formal analysis, visualisation, writing – original draft preparation. MC: conceptualization, formal analysis, methodology, visualisation, writing—review and editing, supervision. APFRLB: visualisation, validation, writing—review and editing. KRG: visualisation, validation, writing—review and editing. CD: conceptualization,

funding acquisition, methodology, project administration, resources, supervision, validation, visualisation, writing—review and editing.

Funding Open Access funding enabled and organized by Projekt DEAL.

Declarations

Conflict of interest The authors declare that they have no conflict of interest.

Open Access This article is licensed under a Creative Commons Attribution 4.0 International License, which permits use, sharing, adaptation, distribution and reproduction in any medium or format, as long as you give appropriate credit to the original author(s) and the source, provide a link to the Creative Commons licence, and indicate if changes were made. The images or other third party material in this article are included in the article's Creative Commons licence, unless indicated otherwise in a credit line to the material. If material is not included in the article's Creative Commons licence and your intended use is not permitted by statutory regulation or exceeds the permitted use, you will need to obtain permission directly from the copyright holder. To view a copy of this licence, visit <http://creativecommons.org/licenses/by/4.0/>.

References

- Abreu JS, Domit C, Zappes CA (2017) Is there dialogue between researchers and traditional community members? The importance of integration between traditional knowledge and scientific knowledge to coastal management. *Ocean Coast Manag* 141:10–19. <https://doi.org/10.1016/j.ocecoaman.2017.03.003>
- Afonso MG, Chaves PTC (2021) A pesca de emalhe costeiro de pequena escala no litoral do Paraná: um estudo de caso para a conservação. *Biodiver Conser Mar*. https://doi.org/10.37002/revis_tacepsul.vol10.1754e2021001
- Andriquetto-Filho JM (1993) Institutional prospects in managing coastal environmental conservation units in Paraná State, Brazil. In: Coastal Zone '93, Proceedings 8th Symposium on Coastal and Ocean Management, 1, New Orleans, pp 2354–2368
- Azevedo AF, Lailson-Brito J, Dorneles PR, Van Sluys M, Cunha HA, Fragoso ABL (2009) Human-induced injuries to marine tucuxis (*Sotalia guianensis*) (Cetacea: Delphinidae) in Brazil. *Mar Biodivers Rec* 2:1–5. <https://doi.org/10.1017/S1755267208000262>
- Azevedo AF, Carvalho RR, Kajin M, Van Sluys M, Bisi TL, Cunha HA, Lailson-Brito J Jr (2017) The first confirmed decline of a delphinid population from Brazilian waters: 2000–2015 abundance of *Sotalia guianensis* in Guanabara Bay, south-eastern Brazil. *Ecol Indic* 79:1–10. <https://doi.org/10.1016/j.ecolind.2017.03.045>
- Baird RW, Gorgone AM (2005) False killer whale dorsal fin disfigurements as a possible indicator of long-line fishery interactions in Hawaiian waters. *Pac Sci* 59(4):593–601. <https://doi.org/10.1353/psc.2005.0042>
- Baker I, O'Brien J, Mchugh K, Berrow S (2017) An ethogram for bottlenose dolphins (*Tursiops truncatus*) in the Shannon estuary. Ireland. *Aquat Mamm* 43(6):594–613. <https://doi.org/10.1578/AM.43.6.2017.594>
- Barletta M, Cysneiros FJA, Lima ARA (2016) Effects of dredging operations on the demersal fish fauna of a South American tropical–subtropical transition estuary. *J Fish Biol* 89:1–31. <https://doi.org/10.1111/jfb.12999>
- Barreto AS, Rocha-Campos CC, Rosas FW, Júnior JMS., Dalla Rosa L, Flores PAC, Silva VMF (2011) Plano de Ação Nacional para a Conservação dos Mamíferos Aquáticos: Pequenos Cetáceos. Brasília: Instituto Chico Mendes de Conservação da Biodiversidade, ICMBio
- Batista RLG, Alvarez MR, Reis MSS, Cremer MJ, Schiavetti A (2014) Site fidelity and habitat use of the Guiana dolphin, *Sotalia guianensis* (Cetacea: Delphinidae), in the estuary of the Paraguaçu River, northeastern Brazil. *North-West J Zool* 10(1):93–100
- Bittencourt L, Lima IMS, Andrade LG, Carvalho RR, Bisi TL, Lailson-Brito J Jr, Azevedo AF (2017) Underwater noise in an impacted environment can affect Guiana dolphin communication. *Mar Pollut Bull* 114(2):1130–1134. <https://doi.org/10.1016/j.marpolbul.2016.10.037>
- Bolker BM, Brook ME, Clark CJ, Geange SW, Poulsen JR, Stevens MHH, White J-SS (2009) Generalized linear mixed models: a practical guide for ecology and evolution. *Trends Ecol Evol* 24:127–135. <https://doi.org/10.1016/j.tree.2008.10.008>
- Bonin CA, Lewallen EA, Van Wijnen AJ, Cremer MJ, Simões-Lopes PC (2017) Habitat preference and behaviour of the Guiana dolphin (*Sotalia guianensis*) in a well-preserved estuary off southern Brazil. *Pak J Zool* 49(6):2235–2242. <https://doi.org/10.17582/journal.pjz/2017.49.6.2235.2242>
- Burnham KP, Anderson DR (2002) Model selection and multimodel inference: a practical information-theoretic approach. Springer, New York
- Cantor M, Wedekin LL, Guimarães PR, Daura-Jorge FG, Rossi-Santos MR, Simões-Lopes PC (2012) Disentangling social networks from spatiotemporal dynamics: the temporal structure of a dolphin society. *Anim Behav* 84:641–651. <https://doi.org/10.1016/j.anbehav.2012.06.019>
- Cardoso FD, Dauner ALL, Martins CC (2016) A critical and comparative appraisal of polycyclic aromatic hydrocarbons in sediments and suspended particulate material from a large South American subtropical estuary. *Environ Pollut* 214:219–229. <https://doi.org/10.1016/j.envpol.2016.04.011>
- Castrillon J, Bengtson Nash S (2020) Evaluating cetacean body condition; a review of traditional approaches and new developments. *Ecol Evol* 10(12):6144–6162. <https://doi.org/10.1002/ece3.6301>
- Chabanne D, Harrison LM, Holyoake C, Finn H, Stephens N, Bejder L (2012) Swan Canning Riverpark dolphin population ecology & health investigations (Final report to the Swan River Trust for Project RSP10MUR03). Australia, Murdoch University: Cetacean Research Unit
- Chan SCY, Karczmarski L (2019) Epidermal lesions and injuries of coastal dolphins as indicators of ecological health. *EcoHealth* 16:576–582. <https://doi.org/10.1007/s10393-019-01428-0>
- Choueri RB, Cesar A, Torres RJ, Abessa DMS, Morais RD, Pereira CDS, Nascimento MRL, Mozeto AA, Riba I, DeIvalls TA (2009) Integrated sediment quality assessment in Paranaguá Estuarine System, southern Brazil. *Ecotox Environ Saf* 72:1824–1831. <https://doi.org/10.1016/j.ecoenv.2008.12.005>
- Choy ES, Campbell KL, Berenbrink M, Roth JD, Loseto LL (2019) Body condition impacts blood and muscle oxygen storage capacity of free-living beluga whales (*Delphinapterus leucas*). *J Exp Biol* 222:1–11. <https://doi.org/10.1242/jeb.191916>
- Christiansen F, Víkingsson GA, Rasmussen MH, Lusseau D (2014) Female body condition affects foetal growth in a capital breeding mysticete. *Funct Ecol* 28:579–588. <https://doi.org/10.1111/1365-2435.12200>
- Christiansen F, Dawson SM, Durban JW, Fearnbach H, Miller CA, Bejder L, Uhart M, Sironi M, Corkeron P, Rayment W, Leunissen E, Haria E, Ward R, Warick HA, Kerr I, Lynn MS, Pettis HM, Moore MJ (2020) Population comparison of right whale body condition reveals poor state of the North Atlantic right whale. *Mar Ecol Prog Ser* 640:1–16. <https://doi.org/10.3354/meps13299>
- Collier M, Ali S, Mann J, Bansal S (2020) Impacts of human disturbance in marine mammals: Do behavioral changes translate to

- disease consequences? *EcoEvoRxiv*. <https://doi.org/10.32942/osf.io/9pr8g>
- Combi T, Taniguchi S, Ferreira PAL, Mansur AV, Figueira RCL, Mahiques MM, Montone RC, Martins CC (2013) Sources and temporal patterns of polychlorinated biphenyls around a large South American grain-shipping port (Paranaguá Estuarine System, Brazil). *Arch Environ Con Tox* 64(4):573–582. <https://doi.org/10.1007/s00244-012-9872-2>
- Crossland CJ, Baird D, Ducrotoy JP, Lindeboom H, Buddemeier RW, Dennison WC, Maxwell BA, Smith SV, Swaney DP (2006) The coastal zone—a domain of global interactions. In: Crossland CJ, Kremer HH, Lindeboom HJ, Crossland JIM, Le Tissier MDA *Coastal Fluxes in the Anthropocene*. Springer, pp 1–37
- Cunha HA, Santos-Neto EB, Carvalho RR, Ikeda JM, Groch KR, Díaz-Delgado J, Guari EB, Brião JA, Oliveira RB, Flach L, Bisi TL, Catão-Dias JL, Azevedo AF, Lailson-Brito J (2021) Epidemiological features of the first unusual mortality event linked to cetacean morbillivirus in the South Atlantic (Brazil, 2017–2018). *Mar Mammal Sci* 37:1375–1390. <https://doi.org/10.1111/mms.12824>
- Deros D, ten Doeschate M, Brownlow AC, Davison NJ, Lusseau D (2020) Toward new ecologically relevant markers of health for cetaceans. *Front Mar Sci* 7:367. <https://doi.org/10.3389/fmars.2020.00367>
- Domiciano IG, Domit C, Broadhurst MK, Koch MS, Bracarense APFRL (2016) Assessing disease and mortality among small cetaceans stranded at a world heritage site in southern Brazil. *PLoS ONE* 11(2):1–17. <https://doi.org/10.1371/journal.pone.0149295>
- Domit C, Caballero S, Miranda A, Fruet P, Torres-Florez JP, Cunha H, Farro AP, Azevedo A, Bisi T, Briceño Y, Cremer MJ, Tardin R, Barreto AS, Bertozzi CP, Lailson-Brito J Jr, Barrios-Garrido H, Van Belleghem T, May-Collado L, Di Tullio J, Bracarense APL, Cantor M, Andriolo A (2021) Report of the *Sotalia guianensis* pre-assessment workshop: main results and status of the current knowledge. *J Cetacean Res Manag* (suppl.) 22:333–378
- Domit C (2010) Ecologia comportamental do boto-cinza, *Sotalia guianensis* (van Bénédén, 1864), no Complexo Estuarino de Paranaguá, estado do Paraná, Brasil. Thesis, Federal University of Paraná
- Dorneles PR, Lailson-Brito J, Fernandez MAS, Vidal LG, Barbosa LA, Azevedo AF, Fragoso ABL, Torres JPM, Malm O (2008) Evaluation of cetacean exposure to organotin compounds in Brazilian waters through hepatic total tin concentrations. *Environ Pollut* 156:1268–1276. <https://doi.org/10.1016/j.envpol.2008.03.007>
- Dorneles PR, Schilithz PF, Paiva TC, Flach L, Barbosa LA, Domit C, Cremer MJ, Azevedo-Silva CE, Azevedo AF, Malm O, Lepoint G, Bisi TL, Das K, Lailson-Brito J (2020) Total tin (TSn) biomagnification: evaluating organotin trophic flow and dispersion using hepatic TSn concentrations and stable isotope (C, N) data of nektonic organisms from Brazil. *Mar Environ Res* 161:1–11. <https://doi.org/10.1016/j.marenvres.2020.105063>
- Duignan PJ, Stephens NS, Robb K (2020) Fresh water skin disease in dolphins: a case definition based on pathology and environmental factors in Australia. *Sci Rep-UK* 10(21979):1–17. <https://doi.org/10.1038/s41598-020-78858-2>
- Flach L, Alonso MB, Marinho T, Van Waerebeek KU, Van Bressemer MF (2019) Clinical signs in free-ranging Guiana dolphins *Sotalia guianensis* during a morbillivirus epidemic: case study in Sepetiba Bay. *Brazil Dis Aquat Organ* 133(3):175–180. <https://doi.org/10.3354/dao03343>
- Fury CA, Reif JS (2012) Incidence of poxvirus-like lesions in two estuarine dolphin populations in Australia: links to flood events. *Sci Total Environ* 416:536–540. <https://doi.org/10.1016/j.scitotenv.2011.11.056>
- Gonzalvo J, Giovos I, Mazzariol S (2015) Prevalence of epidermal conditions in common bottlenose dolphins (*Tursiops truncatus*) in the Gulf of Ambracia, western Greece. *J Exp Mar Biol Ecol* 463:32–38. <https://doi.org/10.1016/j.jembe.2014.11.004>
- Grech A, Bos M, Brodie J, Coles R, Dale A, Gilbert R, Hamann M, Marsh H, Neil K, Pressey RL, Rasheed MA, Sheaves M, Smith A (2013) Guiding principles for the improved governance of port and shipping impacts in the Great Barrier Reef. *Mar Pollut Bull* 75:8–20. <https://doi.org/10.1016/j.marpolbul.2013.07.013>
- Groch KR, Colosio AC, Marcondes MCC, Zucca D, Diaz-Delgado J, Niemeyer C, Marigo J, Brandão PE, Fernández A, Catão-Dias JL (2014) Novel cetacean morbillivirus in Guiana dolphin. *Brazil Emerg Infect Dis* 20(3):511–513. <https://doi.org/10.3201/eid2003.131557>
- Groch KR, Santos-Neto EB, Diaz-Delgado J, Ikeda JMP, Carvalho RR, Oliveira RB, Guari EB, Bisi TL, Azevedo AF, Lailson-Brito J, Catão-Dias JL (2018) Guiana dolphin unusual mortality event and link to cetacean morbillivirus. *Brazil Emerg Infect Dis* 24(7):1349–1354. <https://doi.org/10.3201/eid2407.180139>
- Groch KR, Díaz-Delgado J, Santos-Neto EB, Ikeda JMP, Carvalho RR, Oliveira RB, Guari EB, Flach L, Sierra E, Godinho AI, Fernández A, Keid L, Soares R, Kanamura C, Favero C, Ferreira-Machado E, Sacristán C, Porter B, Bisi T, Azevedo A, Lailson-Brito J, Catão-Dias J (2020) The pathology of cetacean morbillivirus infection and comorbidities in Guiana dolphins during an unusual mortality event (Brazil 2017–2018). *Vet Pathol* 57(6):845–857. <https://doi.org/10.1177/0300985820954550>
- Halpern BS, Walbridge S, Selkoe KA, Kappel CV, Micheli F, D'Agrosa C, Bruno JF, Casey KS, Ebert C, Fox HE, Fujita R, Heinemann D, Lenihan HS, Madin EMP, Perry MT, Selig ER, Spalding M, Steneck R, Watson R (2008) A global map of human impact on marine ecosystems. *Science* 319:948–952. <https://doi.org/10.1126/science.1149345>
- Hammond PS, Mizroch SA, Donovan GP (1990) Individual recognition of cetaceans: Use of photo-identification and other techniques to estimate population parameters. *Rep Intl Whaling Comm. Special Issue* 12
- Hartig F (2020) *DHARMA*: Residual diagnostics for hierarchical (multi-level/mixed) regression models. R package version 0.2.7. <https://CRAN.R-project.org/package=DHARMA>. Accessed 29 April 2020
- Joblon MJ, Pokras MA, Morse B, Harry CT, Rose KS, Sharp SM, Niemeyer ME, Patchett KM, Sharp WB, Moore MJ (2014) Body condition scoring system for delphinids based on short-beaked common dolphins (*Delphinus delphis*). *J Mar Anim Ecol* 7(2):5–13
- Kajiwara N, Matsuoka S, Iwata H, Tanabe S, Rosas FCW, Fillmann G, Readman JW (2004) Contamination by persistent organochlorines in cetaceans incidentally caught along Brazilian coastal waters. *Arch Environ Con Tox* 46:124–134. <https://doi.org/10.1007/s00244-003-2239-y>
- Karczmarski L, Chan SCY, Rubenstein DI, Chui SYS, Cameron EZ (2022a) Individual identification and photographic techniques in mammalian ecological and behavioural research — Part 1: Methods and concepts. *Mamm Biol* (Special Issue) 102(3). <https://link.springer.com/journal/42991/volumes-and-issues/102-3>
- Karczmarski L, Chan SCY, Chui SYS, Cameron EZ (2022b) Individual identification and photographic techniques in mammalian ecological and behavioural research — Part 2: Field studies and applications. *Mamm Biol* (Special Issue) 102(4). <https://link.springer.com/journal/42991/volumes-and-issues/102-4>
- Kastelein RA, Helder-Hoek L, Jennings N, van Kester R, Huisman R (2019) Reduction in body mass and blubber thickness of harbor porpoises (*Phocoena phocoena*) due to near-fasting for 24 hours in four seasons. *Aquat Mamm* 45(1):37–47
- Kiszka J, Pelourdeau D, Ridoux V (2008) Body scars and dorsal fin disfigurements as indicators interaction between small cetaceans and fisheries around the Mozambique channel island of Mayotte. *West Indian Ocean J Mar Sci* 7(2):185–193. <https://doi.org/10.4314/wiojms.v7i2.48276>

- Kiszka J, Van Bresse MF, Pusineri C (2009) Lobomycosis-like disease and other skin conditions in Indo-Pacific bottlenose dolphins *Tursiops aduncus* from the Indian Ocean. *Dis Aquat Organ* 84(2):151–157. <https://doi.org/10.3354/dao02037>
- Lailson-Brito J, Dorneles PR, Azevedo-Silva CE, Azevedo AF, Vidal LG, Zanelatto RC, Lozinski CPC, Azeredo A, Fragoso ABL, Cunha HA, Torres JPM, Malm O (2010) High organochlorine accumulation in blubber of Guiana dolphin, *Sotalia guianensis*, from Brazilian coast and its use to establish geographical differences among populations. *Environ Pollut* 158:1800–1808. <https://doi.org/10.1016/j.envpol.2009.11.002>
- Leone AB, Ferraro GB, Boitani L, Blasi MF (2019) Skin marks in bottlenose dolphins (*Tursiops truncatus*) interacting with artisanal fishery in the central Mediterranean Sea. *PLoS ONE* 14(2):1–18. <https://doi.org/10.1371/journal.pone.0211767>
- Maldini D, Riggan J, Cecchetti A, Cotter MP (2010) Prevalence of epidermal conditions in California coastal bottlenose dolphins (*Tursiops truncatus*) in Monterey Bay. *Ambio* 39(7):455–462. <https://doi.org/10.1007/s13280-010-0066-8>
- Manhães BMR, Santos-Neto EB, Tovar LR, Guari EB, Flach L, Kasper D, Galvão PMA, Malm O, Gonçalves RA, Bisi TL, Azevedo AF, Lailson-Brito J (2021) Changes in mercury distribution and its body burden in delphinids affected by a morbillivirus infection: Evidences of methylmercury intoxication in Guiana dolphin. *Chemosphere* 263:1–11. <https://doi.org/10.1016/j.chemosphere.2020.128286>
- Moura JF, Hauser-Davis RA, Lemos L, Emin-Lima R, Siciliano S (2014) Guiana dolphins (*Sotalia guianensis*) as marine ecosystem sentinels: ecotoxicology and emerging diseases. *Rev Environ Contam T* 228:1–29. https://doi.org/10.1007/978-3-319-01619-1_1
- Moura SPG, Cantor M, Broadhurst MK, Domit C (2021) Environmental and behavioral factors influencing individual variation in spatial use by Guiana dolphins (*Sotalia guianensis*). *J Mammal*. <https://doi.org/10.1093/jmammal/gyab056>
- Murdoch ME, Reif JS, Mazzoil M, McCulloch SD, Fair PA, Bossart GD (2008) Lobomycosis in bottlenose dolphins (*Tursiops truncatus*) from the Indian River Lagoon, Florida: Estimation of prevalence, temporal trends, and spatial distribution. *EcoHealth* 5(3):289–297. <https://doi.org/10.1007/s10393-008-0187-8>
- Possatto FE, Broadhurst MK, Spach HL, Winemiller KO, Millar RB, Santos KM, Lamour MR (2016) Mapping the spatio-temporal distribution of threatened batoids to improve conservation in a subtropical estuary. *J Fish Biol* 89:1098–1104. <https://doi.org/10.1111/jfb.12972>
- Powell SN, Wallen MM, Bansal S, Mann J (2018) Epidemiological investigation of tattoo-like skin lesions among bottlenose dolphins in Shark Bay, Australia. *Sci Total Environ* 630:774–780. <https://doi.org/10.1016/j.scitotenv.2018.02.202>
- Powell SN, Wallen MM, Miketa ML, Krzyszczyk E, Foroughirad V, Bansal S, Mann J (2020) Sociality and tattoo skin disease among bottlenose dolphins in Shark Bay, Australia. *Behav Ecol* 31(2):459–466. <https://doi.org/10.1093/beheco/arz207>
- Pugliarese KR, Bogomolni A, Touhey KM, Herzig SM, Harry CT, Moore MJ (2007) Marine Mammal Necropsy: An introductory guide for stranding responders and field biologists. Massachusetts: National Oceanic and Atmospheric Association, Woods Hole Oceanographic Institution, WHOI 2007-06. Technical Report
- R Core Team (2019) R: A language and environment for statistical computing. R Foundation for Statistical Computing, Vienna, Austria. <https://www.R-project.org/>
- Reif JS, Mazzoil MS, McCulloch SD, Varela RA, Goldstein JD, Fair PA, Bossart GD (2006) Lobomycosis in Atlantic bottlenose dolphins from the Indian River Lagoon. *Florida JAVMA-J Am Vet Med A* 228(1):104–108. <https://doi.org/10.2460/javma.228.1.104>
- Reif JS, Peden-Adams MM, Romano TA, Rice CD, Fair PA, Bossart GD (2009) Immune dysfunction in Atlantic bottlenose dolphins (*Tursiops truncatus*) with lobomycosis. *Med Mycol* 47:125–135. <https://doi.org/10.1080/13693780802178493>
- Rossi-Santos MR, Wedekin LL, Monteiro-Filho ELA (2007) Residence and site fidelity of *Sotalia guianensis* in the Caravelas river estuary, eastern Brazil. *J Mar Biol Assoc UK* 87(1):207–212. <https://doi.org/10.1017/S0025315407055683>
- Rotstein DS, Burdett LG, McLellan W, Schwacke L, Rowles T, Terio KA, Schultz S, Pabst A (2009) Lobomycosis in offshore bottlenose dolphins (*Tursiops truncatus*). *North Carolina Emerg Infect Dis* 15(4):588–590. <https://doi.org/10.3201/eid1504.081358>
- Rowe LE, Currey RJC, Dawson SM, Johnson D (2010) Assessment of epidermal condition and calf size of Fiordland bottlenose dolphin *Tursiops truncatus* populations using dorsal fin photographs and photogrammetry. *Endanger Species Res* 11:83–89. <https://doi.org/10.3354/esr00256>
- Sacristán C, Esperón F, Ewbank AC, Kolesnikovas CKM, Catão-Dias JL (2017) *Paracoccidioidomycosis ceti* in an Atlantic bottlenose dolphin (*Tursiops truncatus*), Brazil. *Transbound Emerg Dis* 65(2):585–587. <https://doi.org/10.1111/tbed.12781>
- Sacristán C, Esperón F, Marigo J, Ewbank AC, de Carvalho RR, Groch KR, de Castilho PV, Sánchez-Sarmiento AM, Costa-Silva S, Ferreira-Machado E, Gonzales-Viera O, Daura-Jorge F, Santos-Neto E, Lailson-Brito J, Azevedo AF, Simões-Lopes PC, Neves CG, Catão-Dias J (2018) Molecular identification and microscopic characterization of poxvirus in a Guiana dolphin and a common bottlenose dolphin. *Brazil Dis Aquat Organ* 130(3):177–185. <https://doi.org/10.3354/dao03271>
- Sanchez-Sarmiento AM, Carvalho VL, Diaz-Delgado J, Ressler RA, Fernandes N, Guerra JM, Sacristán C, Groch KR, Silvestre-Perez N, Ferreira-Machado E, Costa-Silva S, Navas-Suárez P, Meirelles ACO, Favero C, Marigo J, Bertozzi CP, Colosio AC, Marcondes MCC, Cremer MJ, Silva NS, Neto JSF, Keid LB, Soares R, Sierra E, Fernández A, Catão-Dias JL (2019) Molecular, serological, pathological, immunohistochemical and microbiological investigation of *Brucella* spp. in marine mammals of Brazil reveals new cetacean hosts. *Transbound Emerg Dis* 66(4):1674–1692. <https://doi.org/10.1111/tbed.13203>
- Sanino GP, Van Bresse MF, Van Waerebeek K, Pozo N (2014) Skin disorders of coastal dolphins at Añihué reserve, Chilean Patagonia: a matter of concern. *Bol Museo Nac Hist Nat* 63:127–157
- Santos MCO, Oshima JEF, Pacífico ES, Silva E (2010) Group size and composition of Guiana dolphins (*Sotalia guianensis*) (Van Bénèden, 1864) in the Paranaguá Estuarine Complex. *Brazil Braz J Biol* 70(1):111–120. <https://doi.org/10.1590/S1519-69842010001001015>
- Seade GCC, Cerqueira VD, Sierra E, Chaves JF, Moura MAO, Montao DP, Riet-Correa G, Oliveira CA, Siciliano S, Emin-Lima R, Costa AF, Fernández A, Júnior PSB (2017) Herpesviral infection in a Guiana dolphin (*Sotalia guianensis*) from the northern coast of Brazil. *J Vet Diagn Invest* 29(6):877–879. <https://doi.org/10.1177/1040638717727794>
- Secchi E, Santos MCdeO, Reeves R (2019) *Sotalia guianensis* (errata version published in 2019). The IUCN Red List of Threatened Species 2018: e.T181359A144232542. <https://doi.org/10.2305/IUCN.UK.2018-2.RLTS.T181359A144232542.en>. Accessed 6 June 2020
- Simões-Lopes PC, Paula GS, Both MC, Xavier FM, Scaramello AC (1993) First case of lobomycosis in a bottlenose dolphin from southern Brazil. *Mar Mammal Sci* 9(3):329–331. <https://doi.org/10.1111/j.1748-7692.1993.tb00462.x>
- Soares CR, Lamour MR (2008) Atividade portuária na Baía de Paranaguá (PR): histórico e características de navegação, canais de acesso, berços de atracação, bacias de evolução e áreas de fundeio. In: Boldrini EB, Soares CR, Vedor De Paula E Dragagens portuárias no Brasil: Engenharia, tecnologia e meio ambiente. Antonina: Associação de Defesa do Meio Ambiente

- e Desenvolvimento de Antonina (ADEMADAN), Faculdades Integradas Espírita (UNIBEM), Secretaria de Ciência e Tecnologia para Inclusão Social (MCT), pp 26–45
- Thompson PM, Hammond PS (1992) The use of photography to monitor dermal disease in wild bottlenose dolphins (*Tursiops truncatus*). *Ambio* 21(2):135–137
- Todd VLG, Todd IB, Gardiner JC, Morrin ECN, MacPherson NA, DiMarzio NA, Thomsen F (2015) A review of impacts of marine dredging activities on marine mammals. *ICES J Mar Sci* 72(2):328–340. <https://doi.org/10.1093/icesjms/fsu187>
- Torres RJ, Abessa DMS, Santos FC, Maranhão LA, Davanso MB, do Nascimento MRL, Mozeto AA. (2009) Effects of dredging operations on sediment quality: contaminant mobilization in dredged sediments from the Port of Santos, SP, Brazil. *J Soil Sediment* 9:420–432. <https://doi.org/10.1007/s11368-009-0121-x>
- Townsend Jr FI, Staggs L (2021) Atlas of skin diseases of small cetaceans. Todd Speakman Photo Editor, MS Hendrick Design & Photography. ISBN: 978-0-578-49642-9
- Trevizani TH, Domit C, Vedolin MC, Angeli JLF, Figueira RCL (2019) Assessment of metal contamination in fish from estuaries of southern and southeastern Brazil. *Environ Monit Assess* 191(5):1–16. <https://doi.org/10.1007/s10661-019-7477-1>
- Trevizani TH, Figueira RCL, Santos MCO, Domit C (2021) Mercury in trophic webs of estuaries in the southwest Atlantic Ocean. *Mar Pollut Bull* 167:1–10. <https://doi.org/10.1016/j.marpolbul.2021.112370>
- Van Bressem MF, Gaspar R, Aznar FJ (2003) Epidemiology of tattoo skin disease in bottlenose dolphins *Tursiops truncatus* from the Sado estuary. *Portugal Dis Aquat Organ* 56(2):171–179. <https://doi.org/10.3354/dao056171>
- Van Bressem MF, Van Waerebeek K, Reyes JC, Félix F, Echegaray M, Siciliano S, Di Benedetto AP, Flach L, Viddi F, Avila IC, Herrera JC, Tobón IC, Bolaños-Jiménez J, Moreno IB, Ott PH, Sanino GP, Castineira E, Montes D, Crespo E, Flores PAC, Haase B, Mendonça de Souza SMF, Laeta M, Fragoso AB (2007) A preliminary overview of skin and skeletal diseases and traumata in small cetaceans from South American waters. *Lat Am J Aquat Mamm* 6(1):7–42. <https://doi.org/10.5597/lajam00108>
- Van Bressem MF, Santos MCO, Oshima JEF (2009a) Skin diseases in Guiana dolphins (*Sotalia guianensis*) from the Paranaguá estuary, Brazil: A possible indicator of a compromised marine environment. *Mar Environ Res* 67(2):63–68. <https://doi.org/10.1016/j.marenvres.2008.11.002>
- Van Bressem MF, Van Waerebeek K, Aznar FJ, Raga JA, Jepson PD, Duignan P, Deaville R, Flach L, Viddi F, Baker JR, Di Benedetto AP, Echegaray M, Genov T, Reyes J, Felix F, Gaspar R, Ramos R, Peddemors V, Sanino GP, Siebert U (2009b) Epidemiological pattern of tattoo skin disease: a potential general health indicator for cetaceans. *Dis Aquat Organ* 85:225–237. <https://doi.org/10.3354/dao02080>
- Vidal LG, Vannuci-Silva M, Alonso MB, Feo ML, Corcellas C, Bisi TL, Flach L, Fragoso ABL, Silva FJL, Carvalho VL, Meirelles ACO, Domit C, Barbosa LA, Cremer MJ, Azevedo AF, Torres JPM, Malm O, Lailson-Brito J, Eljarrat E (2020) Pyrethroid insecticides along the Southwestern Atlantic coast: Guiana dolphin (*Sotalia guianensis*) as a bioindicator. *Sci Total Environ* 728:1–8. <https://doi.org/10.1016/j.scitotenv.2020.138749>
- Wilson B, Arnold H, Bearzi G, Fortuna CM, Gaspar R, Ingram S, Liret C, Pribanic S, Read AJ, Ridoux V, Schneider K, Urian KW, Wells RS, Wood C, Thompson PM, Hammond PS (1999) Epidermal diseases in bottlenose dolphins: impacts of natural and anthropogenic factors. *P Roy Soc B-Biol Sci* 266(1423):1077–1083. <https://doi.org/10.1098/rspb.1999.0746>
- Yang W-C, Chang W-L, Kwong K-H, Yao Y-T, Chou L-S (2013) Prevalence of epidermal conditions in critically endangered Indo-Pacific humpback dolphins (*Sousa chinensis*) from the waters of western Taiwan. *Pak Vet J* 33(4):505–509

Publisher's Note Springer Nature remains neutral with regard to jurisdictional claims in published maps and institutional affiliations.

Authors and Affiliations

Estela Dibo Soares^{1,2}  · Maurício Cantor^{2,3,4,5,6}  · Ana Paula Frederico Rodrigues Loureiro Bracarense⁷  · Kátia Regina Groch⁸  · Camila Domit^{1,2} 

¹ Laboratório de Ecologia e Conservação, Centro de Estudos do Mar, Universidade Federal do Paraná, Pontal do Paraná, Brazil

² Programa de Pós-Graduação em Sistemas Costeiros e Oceânicos, Centro de Estudos do Mar, Universidade Federal do Paraná, Pontal do Paraná, Brazil

³ Department of Fisheries, Wildlife and Conservation Sciences, Marine Mammal Institute, Oregon State University, Newport, OR, USA

⁴ Department for the Ecology of Animal Societies, Max Planck Institute of Animal Behavior, Radolfzell, Germany

⁵ Departamento de Ecologia e Zoologia, Universidade Federal de Santa Catarina, Florianópolis, Brazil

⁶ School of Animal, Plant and Environmental Sciences, University of the Witwatersrand, Johannesburg, South Africa

⁷ Laboratório de Patologia Animal, Departamento de Medicina Veterinária Preventiva, Universidade Estadual de Londrina, Londrina, Brazil

⁸ Department of Veterinary Pathobiology, Texas A&M University, College Station, TX, USA